

Introduction:

Studies of imaging findings associated with diseases may be aided by a process called spatial normalization. Resizing and registration of images so that structures have similar shape, size, and orientation to a predefined template allows data from subjects to be averaged to increase statistical power for analysis of differences between normal and pathologic states. In addition, the transformation map for a subject or group to the atlas is a descriptor of the variation from the atlas, allowing insights into structural or functional changes that are not visually apparent.

In neuroimaging, the Talairach atlas provides a standard template to which images are normalized prior to analysis (1), however there is no agreed upon atlas for cardiac imaging. We have previously presented an atlas template for cardiac MR (2) calculated using an intensity-based registration algorithm (3). This is an automated process which operates on pixel intensities, without the need for manual methods such as contour tracing.

We have developed a new method for image registration without the problems of intensity based methods. Hierarchical Attribute Matching Mechanism for Elastic Registration (HAMMER) creates an attribute vector for each voxel in the data set that includes information about the voxel as well as elements that reflect the structure of the underlying anatomy (4). The attribute vector, if rich enough, can distinguish between different parts of an image, e.g. most voxels within the myocardium look similar, but have different geometric relationships to the cardiac apex. This method has been applied to registration of MR imaging of brains and spinal lesions and prostate ultrasound images, displaying performance as good as human experts. (5-6)

Purpose:

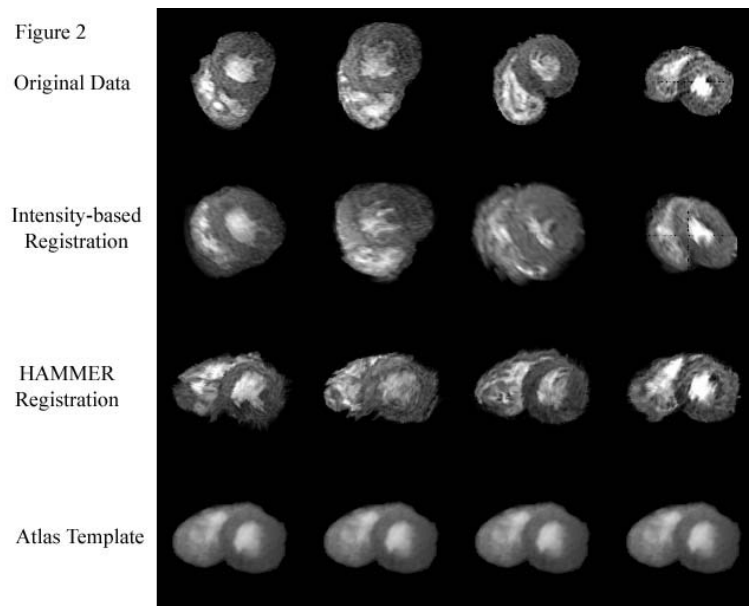
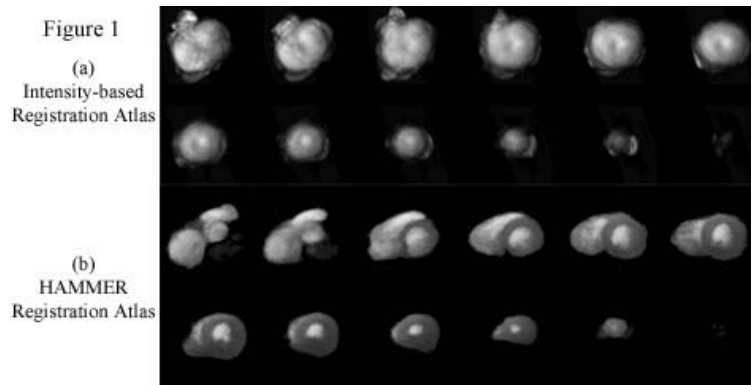
To create an atlas template for cardiac MR imaging using the HAMMER method, and to compare the results with our previous template obtained using intensity-based registration.

Methods:

Short axis cine GRASS images of the heart obtained at end-systole in 20 normal volunteers (mean age 39 years, range 21 to 79) were used. These were the same datasets used for the previous study. A linear transformation was applied first to minimize variability in orientation and overall size of the hearts. All subjects were then registered to a single subject using a version of the HAMMER algorithm adapted for lower resolution cardiac MR images. The atlas template was then created by averaging the 20 registered datasets.

Results:

Figure 1(a) shows the atlas obtained by averaging the 20 subjects after HAMMER registration, demonstrating the superior performance of HAMMER compared to the atlas previously obtained using intensity based registration in figure 1(b). Figure 2 compares registration results obtained with HAMMER versus intensity-based registration for selected subjects. Note the marked improvement in accuracy of the registration, even for subjects whose hearts differed in shape and orientation from the template.



Conclusions:

Application of HAMMER resulted in markedly improved performance over the previous intensity-based registration for construction of a cardiac atlas template. Future work will include incorporation of higher resolution MR and CT datasets to improve the atlas, systematic analysis of the transformation maps for normal and abnormal hearts, and extension of HAMMER to 4-D datasets, which will allow generation of an atlas which represents the average structure and function of the heart.

References:

1. Talairach J and Tournoux P. Co-Planar Stereotactic Atlas of the Human Brain. 1998; Thieme, Stuttgart.
2. Litt HI, Axel L, and Blom A J. Cardiovascular Magnetic Resonance 1999; 1(4):370-371.
3. Woods RP, Grafton ST, Holmes CJ, et. al. JCAT 1998; 22: 141-154.
4. Shen D, Davatzikos C. IEEE Trans. Medical Imaging Nov 2002;21(11):1421-1439.
5. Shen D, Davatzikos C. NeuroImage Jan 2003;18(1):28-41.
6. Davatzikos C, Liu D, Shen D, Herskovits EH. Radiology, Sep 2002;224(3):919-26.