Audiology & Neurotology

Audiol Neurotol 2006;11(suppl 1):49–56
DOI: 10.1159/000095614

Received: January 25, 2006
Accepted after revision: August 2, 2006
Published online: October 6, 2006

Ipsilateral Electric Acoustic Stimulation of the Auditory System: Results of Long-Term Hearing Preservation

Wolfgang K. Gstoettner[a] Silke Helbig[a] Nicola Maier[a] Jan Kiefer[b] Andreas Radeloff[a] Oliver F. Adunka[c]

[a]Department of Otolaryngology, Johann Wolfgang Goethe University Frankfurt am Main, Frankfurt am Main,
[b]Department of Otolaryngology, Klinikum rechts der Isar, Technical University Munich, Munich, Germany;
[c]Department of Otolaryngology, University of North Carolina at Chapel Hill, Chapel Hill, N.C., USA

Key Words
Cochlear implants · Acoustic stimulation · Electric stimulation · Hearing loss · Electric acoustic stimulation · Hearing preservation

Abstract
Objective: To evaluate long-term ipsilateral hearing preservation in patients who underwent cochlear implantation for the combined electric acoustic stimulation of the auditory system. ***Methods:*** This was a prospective observational study conducted at a tertiary referral center. Twenty-three subjects were implanted with the MED-EL C40+ standard or C40+ medium electrode using an atraumatic surgical protocol via an anterior-inferior cochleostomy approach. The desired insertion depth was 18–24 mm or 360°. All patients showed significant low-frequency hearing prior to surgery and monosyllabic word scores did not exceed 40% in the best aided condition. Pure-tone audiometry was performed prior to implantation and at distinct intervals after surgery. ***Results:*** Nine patients (39.1%) showed complete pure-tone audiometric hearing preservation (0–10 dB) over an average of 29 months. Seven subjects (30.4%) showed partial preservation of residual hearing (hearing loss 15–40 dB) until an average of 25 months. Delayed loss of residual hearing was observed in 5 cases (21.7%) and 2 patients (8.6%) completely lost residual hearing during or immediately after surgery. Freiburger Monosyllabic word understanding scores in a group of patients with complete hearing preservation increased from 13.1% preoperatively to 75% in the electric acoustic stimulation condition. ***Conclusion:*** This study documents that complete and partial preservation of ipsilateral hearing after cochlear implantation can be achieved in about 70% of cases over an average period of 27.25 months when using 360° electrode insertions.

Copyright © 2006 S. Karger AG, Basel

Introduction

Until 1993, when Lehnhardt first described the soft surgery technique for inserting intracochlear implants [Lehnhardt, 1993], little effort has been made to protect and preserve inner ear structures during cochlear implantation. Initially, the goal of soft surgery was to ensure the presence of sufficient excitable neuronal structures for electrostimulation. A few years later, Hodges et al. [1997] described measurable residual acoustic hearing after cochlear implantation in about 50% of cases. Although soft surgery techniques were already used by many surgeons at that time, preoperative- and thus postoperative residual hearing were small and did not improve overall

KARGER
Fax +41 61 306 12 34
E-Mail karger@karger.ch
www.karger.com

© 2006 S. Karger AG, Basel
1420–3030/06/0117–0049$23.50/0

Accessible online at:
www.karger.com/aud

Prof. Wolfgang K. Gstoettner, MD, PhD
Department of Otolaryngology, J.W. Goethe University Frankfurt am Main
Theodor-Stern-Kai 7
DE–60590 Frankfurt am Main (Germany)
Tel. +49 69 6301 5163, Fax +49 69 6301 5435, E-Mail gstoettner@em.uni-frankfurt.de

implant performance. In 1999, von Ilberg first described the electric acoustic stimulation (EAS) of the auditory system – a method, which combines residual 'natural' low frequency cochlear function with electrostimulation of a cochlear implant on the same ear – at the University of Frankfurt [von Ilberg et al., 1999]. Preliminary speech discrimination results were promising in that EAS led to markedly improved speech perception in noise compared to the cochlear implant alone mode. Although a lot of progress has been made ever since the introduction of EAS and further reports confirmed initial speech perception data [Kiefer et al., 2005; Gstoettner et al., 2004], most issues in hearing preservation and subsequent combined, ipsilateral EAS have remained unsolved.

It is generally believed that intracochlear trauma caused by insertion of the stimulation electrode contributes significantly to the success or failure of intra- and postoperative hearing preservation [Kiefer et al., 2004]. Therefore, cochlear implant companies provided more atraumatic arrays [Adunka et al., 2004b] and adequate modifications of the soft surgical technique have been developed [Kiefer et al., 2004; Skarzynski et al., 2003]. Despite all these efforts, clinical trials showed that hearing preservation was possible in most – but not all cases [Kiefer et al., 2005; Gstoettner et al., 2004; Skarzynski et al., 2003; Gantz and Turner, 2003; James et al., 2005].

The aim of this report was to evaluate long-term residual hearing in a series of 23 patients who underwent cochlear implantation with the goal of ipsilateral EAS.

Material and Methods

Subjects

Inclusion criteria for patients were bilateral sensoneurinal hearing loss with pure-tone thresholds of <60 dB HL in at least 2 of the frequencies 125, 250 and 500 Hz and of >60 dB at frequencies >1 kHz. Monosyllabic word recognition had to be ≤40% in the best-aided condition. The hearing loss should have been stable over at least 2 years prior to surgery (as assessed via pure-tone audiometry). Most patients had symmetric bilateral hearing loss, otherwise the poorer ear was implanted.

All patients of this prospective observational study have been implanted in Frankfurt. The study protocol was reviewed and approved by the local institutional review board. To determine hearing preservation beyond the acute setting after surgery, a follow-up period of at least 6 months after surgery was chosen. Thus, 23 subjects could be included in this evaluation. All patients were implanted with a MED-EL COMBI 40+ cochlear implant with either a standard 31.5-mm-long electrode or with a shorter electrode array to contribute to the limited insertion depths of EAS (medium electrode). The Combi 40+ M electrode has a reduced contact spacing of 1.9 mm (compared to 2.4 mm in the standard array). Thus, the overall contact distribution length is 22 mm in the Combi 40+ M electrode and 27 mm in the standard electrode.

After surgery, measurements of residual hearing were performed at defined intervals. Typically, all patients underwent fitting of the cochlear implant 3–4 weeks after implantation. To provide good performance with the cochlear implant alone, the ipsilateral hearing aid was provided 3 months after the initial fitting of the cochlear implant speech processor. Residual hearing was assessed at every visit. Also, all patients were advised to report to our clinic in case of any subjective change in their hearing.

Hearing preservation was considered complete when average low frequency (125–750 Hz) hearing loss was less or equal than 10 dB HL compared to preoperative pure-tone thresholds. Respectively, partial preservation was considered in cases of low-frequency hearing loss of more than 15 dB according to preoperative pure-tone thresholds. Long-term preservation was considered for completely and partially preserved hearing of more than 6 months. No detectable low-frequency thresholds were consistent with loss of residual hearing.

Surgical Procedure

In contrast to standard cochlear implantations, the surgical procedure for EAS is performed on a partly functioning inner ear. Thus, this kind of surgery has to be performed as atraumatically as possible – with preservation of vulnerable intracochlear structures like the osseous spiral lamina, the basilar membrane, the spiral ligament, and of course the organ of Corti.

In a large series of human cadaver temporal bone experiments, we were able to demonstrate atraumatic electrode insertions with the MED-EL device [Adunka et al., 2004a]. In those cases, the array was found to be sliding along the inferior part of the lateral wall of the scala tympani. Thus, achieving a similar intracochlear electrode position was the main goal of each in vivo surgery reported herein.

A mastoidectomy and facial recess approach to the middle ear without ossicular chain manipulations was used in all cases of EAS implantations at our institution. Careful opening of the scala tympani was performed via a cochleostomy anterior and strictly inferior to the round window. All drilling procedures at the promontory bone were carried out with slow rotating diamond drills and skeeters (from Stapes surgery) after mucosal bleeding has been stopped entirely. Special care was taken to expose the endostium over an area of approximately 1 mm^2 without opening it. By touching the stapes, inner ear fluid waves were transmitted along the cochlea and hence movements of the intact endostium were visible ('EAS fenestra assay').

Instillation of crystalline steroid solution (Triamcinolon, Volon A®) to the exposed endostium and to the round window for approximately 10 min was performed [Kiefer et al., 2004]. Additionally, the exposed endosteum was covered with a drop of hyaluronic acid (Healon®) before it was opened with a fine needle. Any suction of perilymphatic fluid was avoided. The electrode was then inserted in an inferior-anterior direction to achieve its desired sliding along the inferior and lateral wall of the basal turn's scala tympani. Electrode insertion was carried out slowly to allow compensational outflow of perilymphatic fluid according to the repressed volume of the electrode. Hence, damaging intrascalar hydrodynamic pressure waves were minimized. With the electrode carrier in place, the cochleostomy was sealed with a circular fascial flap.

Electrode insertion depth of 18–24 mm (360°) in the present study was chosen mainly for two reasons: (1) according to 'Greenwood' maps of cochlear frequency locations [Greenwood, 1990, 1996], this insertion length corresponds well to high-frequency regions, which are the aim of electrical stimulation, and (2) insertion depths of one full turn should provide good cochlear implant performance (for combined EAS as well as in case of loss of residual hearing). However, pitch perception from electrical stimulation may be lower than expected from Greenwood map.

Due to variations in cochlear size and diameter, preoperative radiological measurements were performed in order to predict the required insertion depth in mm to achieve a 360° insertion [Adunka et al., 2005]. This was done by using a high-resolution computed tomography-based 3-dimensional placement of reference points. Evaluation of this method showed fairly good accuracies if measurements included the basal and first part of the middle cochlear turn only [Adunka et al., 2005].

Results

A total number of 23 patients with significant residual hearing according to our protocol (15 females, 8 males; mean age at implantation 49.9 years; range 25.9–77.3 years) were implanted between 1999 and 2005 at the University of Frankfurt and could be included in this evaluation. Sixteen patients were implanted in the right ear and 7 patients received an implant in the left ear. The minimum follow-up time was 6 months after implantation.

Despite swelling of the cochlear endosteum in one case, no specific intraoperative findings or postoperative surgical complications were observed. Electrodes were inserted 18–24 mm, which did not always result in 360° insertions – obviously due to significant differences in cochlear size and shape among patients [Zrunek et al., 1980]. As mentioned before, a high-resolution computed tomography protocol was introduced in the late course of the study to predict the length of insertion in order to achieve more exact 360° insertions [Adunka et al., 2005].

At the final follow-up interval, patients were grouped according to their individual long-term hearing preservation outcome. Of the 23 patients, 9 (39.1%) showed complete hearing preservation under the terms of our protocol (average pure-tone threshold shift at 250–750 Hz compared to preoperative hearing less than 10 dB) over 7–70 months (mean 29 months; fig. 1).

In 7 patients, (30.4%) residual low-frequency hearing at the final evaluation was found to be partially preserved (average low-frequency hearing loss >15 dB but clear ipsilateral low-frequency acoustic hearing detectable) and was found to be stable over 6–70 months (mean 25.0 months, fig. 2). In 5 patients (21.7%) hearing could be preserved partially, but low-frequency hearing loss eventually progressed to complete deafness (no measurable acoustic hearing) after 7–18 months (mean 12.6 months) after surgery (fig. 3a–e). In 2 patients (8.6%) no hearing could be preserved and complete hearing loss was found immediately after surgery (fig. 3f–g). Both of the latter patients were implanted in 2000 and thus early in the process of this study.

Freiburger Monosyllabic word understanding scores in the group of patients with complete hearing preservation increased from 13.1% preoperatively to 75% in the EAS condition (fig. 4).

Discussion

This paper documents complete preservation of residual hearing in 9 of 23 patients implanted for EAS. Although 3 of the 9 patients have less than 2 years experience (fig. 1g–i), these patients are considered as having stable long-term preservation of residual hearing. The patients with partial hearing preservation (fig. 2) all had some initial hearing loss immediately after implantation which then proceeded in some cases. Thus, completely preserved immediate postoperative hearing may be used as a predictor for its long-term stability.

Acute postoperative deafness was encountered in less than 10% of our cases. In about 20% of our patients, progression of sensorineural hearing impairment lead to delayed deafness in the implanted ear after 7–18 months. The reason for preserving hearing in some cases and losing it in others is not clear yet. All surgeries were performed by 2 surgeons (W.K.G. and J.K.) who shared their experience.

To provide efficient combination of electric and acoustic stimulation, stable long-term hearing preservation seems to be of great importance. Patients need more time to adapt to EAS than to conventional cochlea implants. Previously, EAS results including short-term hearing preservation outcomes from two centers have been published [Kiefer et al., 2005; Gstoettner et al., 2004]. The current paper, on the other hand, reports on patients who had been implanted in Frankfurt only. Therefore, variations in patient selection, surgical procedure, and medical management have been minimized.

Another approach to EAS is shorter electrode insertions of 6–10 mm. In a multi-center trial involving this concept [Gantz et al., 2005], out of 21 patients, one showed

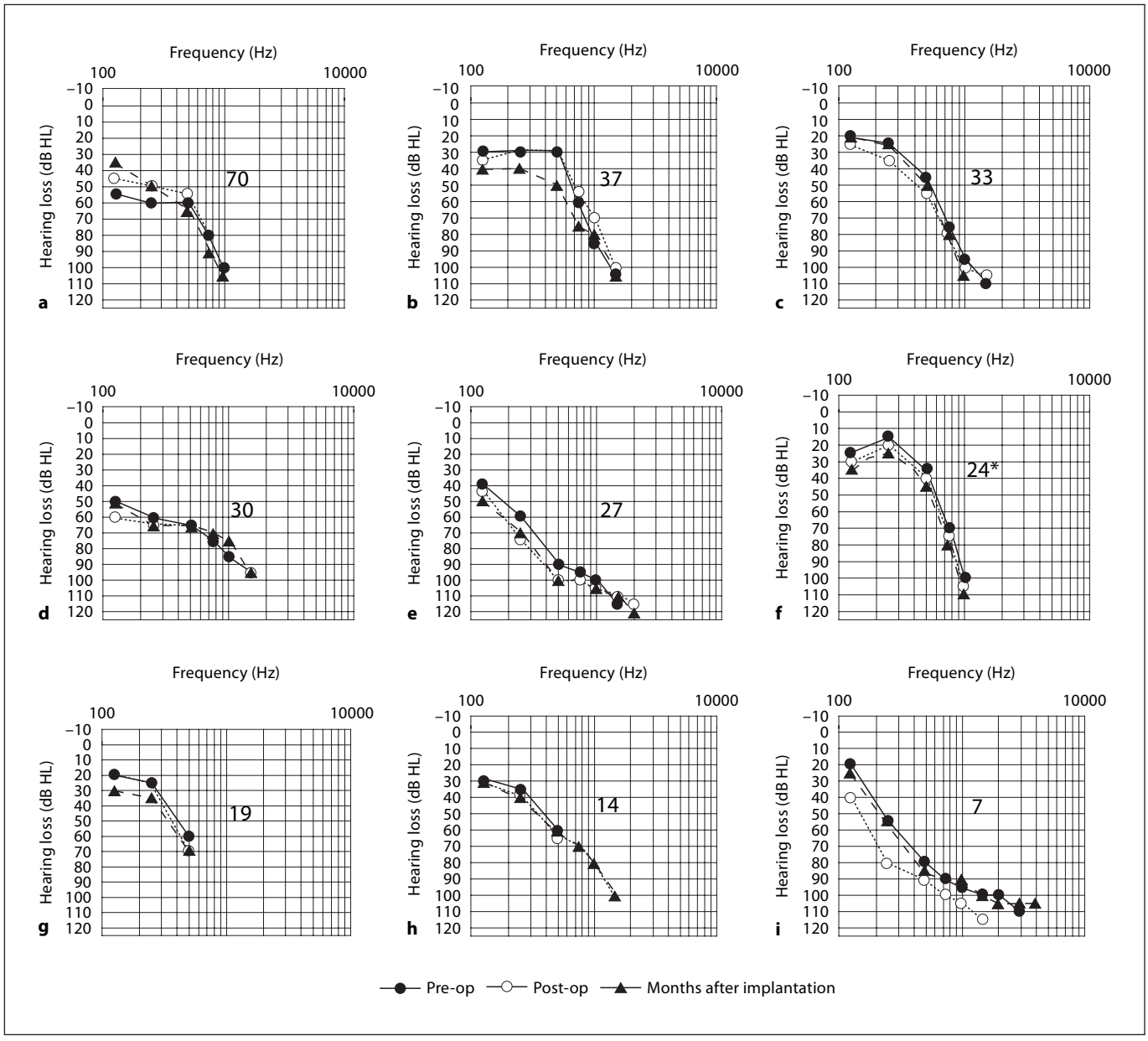

Fig. 1. Audiograms pre- and postoperatively and after 7–70 months of patients with complete hearing preservation. The patient indicated by an asterisk had a complete preservation of the inner ear function as demonstrated by bone conduction measurement. An additional air-bone gap of 15 dB is not illustrated on the audiogram. ● = Before operation; ○ = after operation; ▲ = months after implantation.

a delayed 30-dB drop in average pure-tone thresholds and another lost hearing completely after 2.5 months. Thus, their rate of hearing preservation is superior when compared to deeper insertions as used in this study. However, very limited insertions bear controversies as how to proceed in cases of complete hearing loss, since the cochlear implant alone may not provide sufficient speech perception abilities.

Very recently, first results of a multicenter trial investigating preservation of residual hearing after implantation with a standard length perimodiolar electrode (Nucleus Contour Advance electrode) have been reported

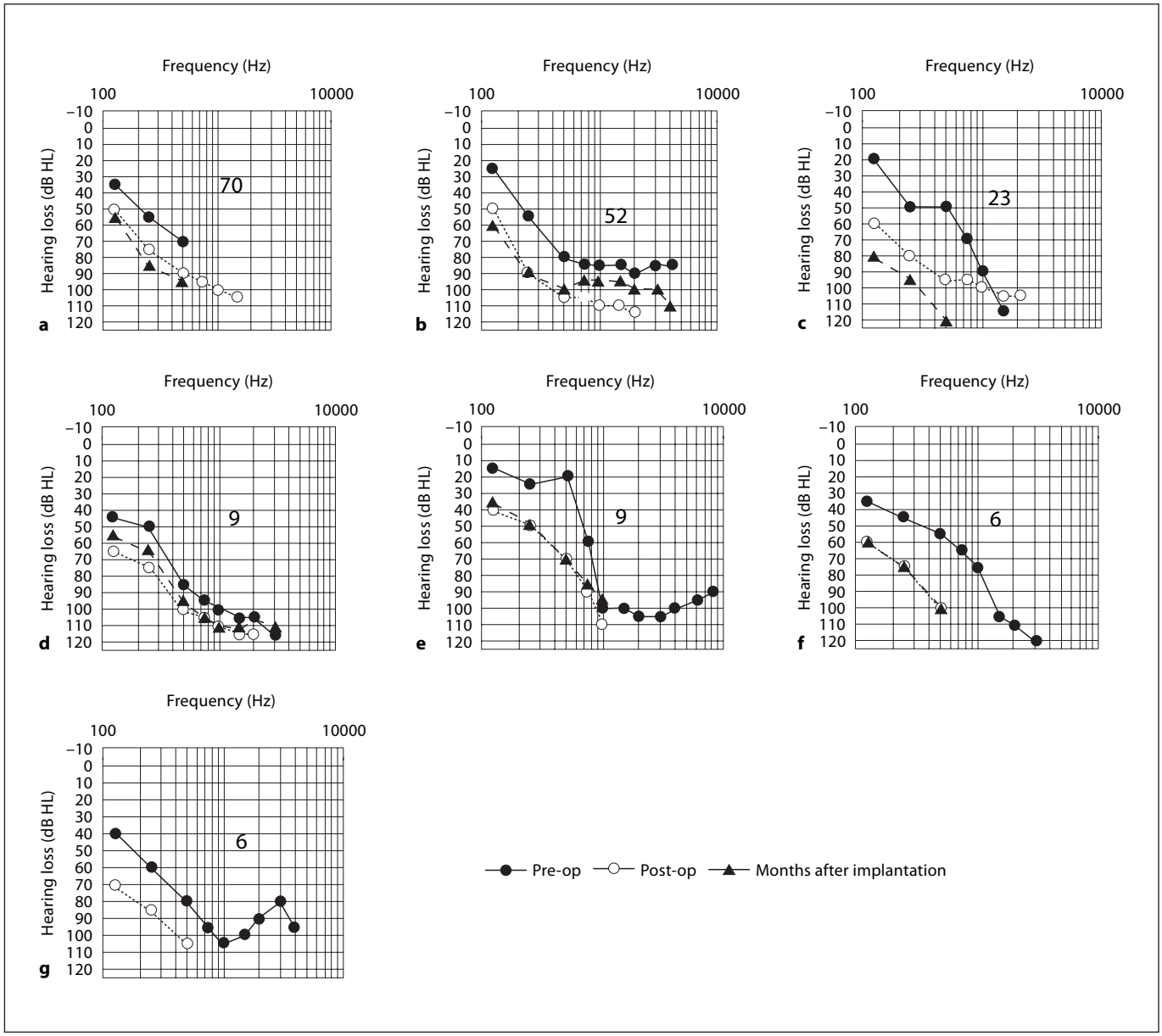

Fig. 2. Audiograms pre- and postoperatively and after 6–70 months of patients with partial hearing preservation. ● = Before operation; ○ = after operation; ▲ = months after implantation.

[James et al., 2005]. Insertion depths in this study were 17–19 mm (300–430°). Although perimodiolar electrodes seem to increase cochlear trauma [Gstoettner et al., 2001; Richter et al., 2001; Aschendorff et al., 2003], in this study only 2 of 12 patients had total hearing loss due to unexpected difficulties during surgery and half of the patients retained sufficient hearing for effective ipsilateral bimodal stimulation. A more recent cadaver study was able to confirm the result of relatively atraumatic insertions with modified perimodiolar electrodes [Adunka et al., in press]. Yet, long-term hearing preservation outcomes are expected with interest.

One of the most important steps of EAS surgery seems to be atraumatic opening of the scala tympani [Briggs et al., 2005]. Alternatively, opening of the round window membrane [Skarzynski et al., 2003] could be a safe access

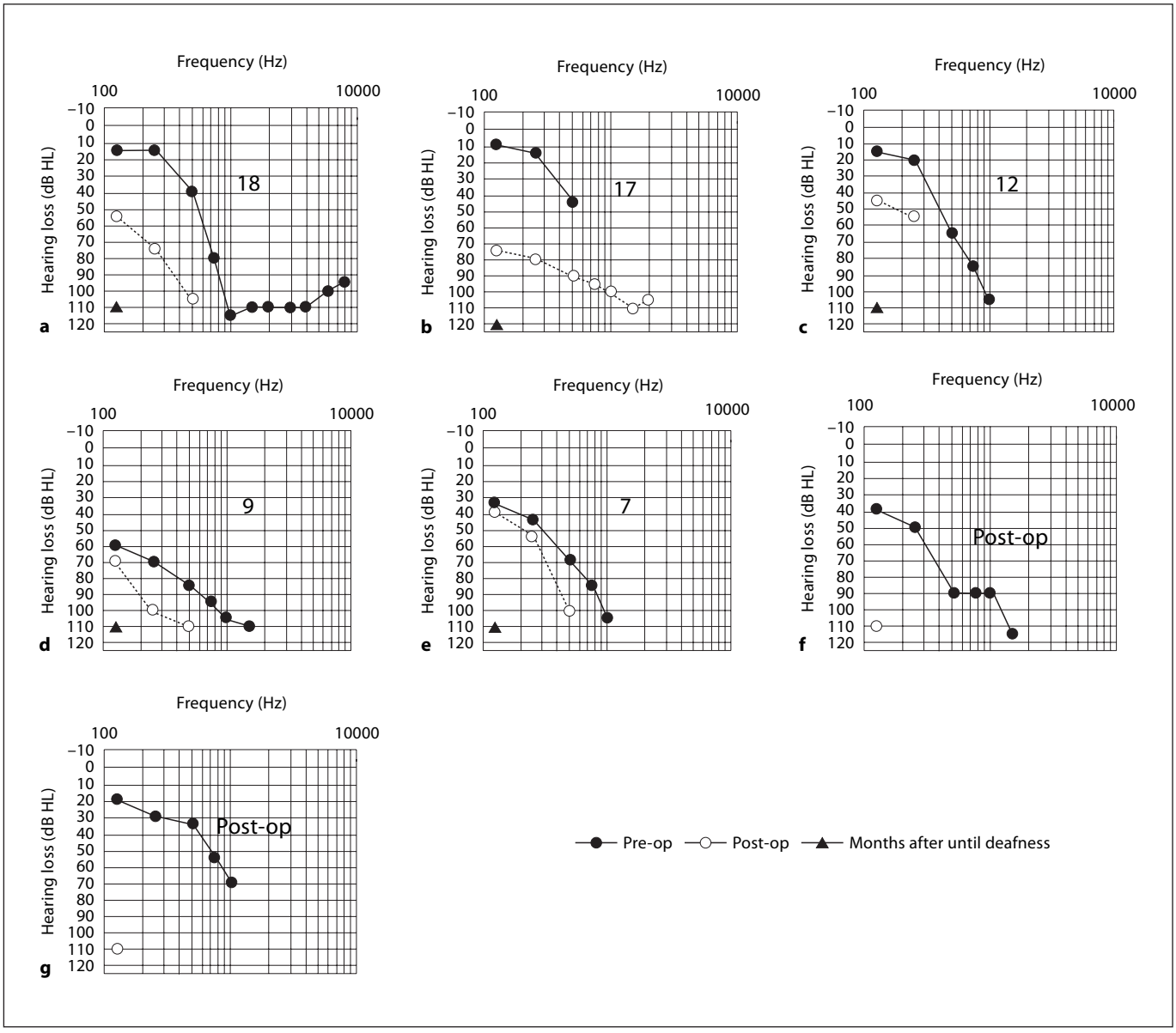

Fig. 3. Audiograms pre- and postoperatively. Two patients with early onset of deafness directly after implantation and 5 patients with late onset of deafness after 7–18 months after implantation. ● = Before operation; ○ = after operation; ▲ = months until deafness.

to scala tympani, avoiding trauma to osseous spiral lamina and to the basilar membrane [Adunka et al., 2004c]. However, basal cochlear anatomy including the round window area shows great variations [Zrunek et al., 1980]. Its exposure through the facial recess seems limited in some cases and thus an approach through the ear canal including raising a tympanomeatal flap might enhance visibility.

At present, basic science and research are trying to depict the exact mechanisms and importance of factors leading to hearing loss after electrode insertion. Interruption of particular pathways that result in hearing loss is the ultimate goal [Scarpidis et al., 2003]. Recent animal experiments [Eshraghi et al., 2005] suggest that hearing loss after cochlear implantation occurs in two stages: an early stage during or immediately after surgery and a de-

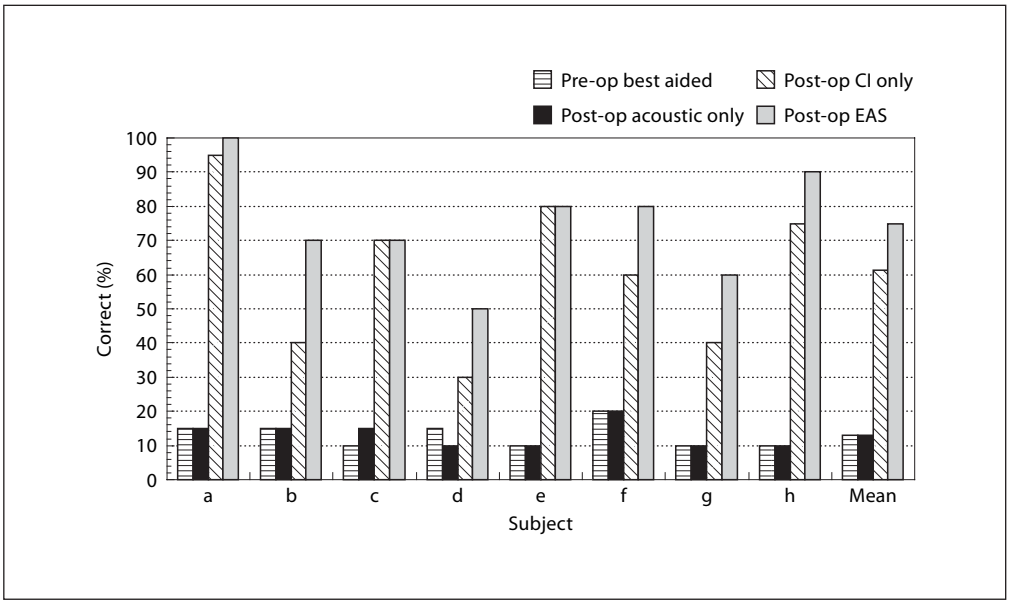

Fig. 4. Pre- and postoperative results of Freiburger monosyllables discrimination for patients with complete preservation of residual hearing. Subjects with at least 1 year of EAS experience are included. a–h correspond to figure 1.

layed stage occurring within the first few weeks after implantation. It is believed that protection from hair cell apoptosis might alter the delayed pathway positively [Scarpidis et al., 2003]. Hence, pharmacological treatment of hearing loss is currently one of the main topics in patient-oriented inner ear research. As part of it, pathways to delivery future pharmaceuticals to their site of action, e.g. the cochlear duct, are currently under investigation [Paasche et al., 2006]. Although sophisticated viral vectors might be the foundation of inner ear treatment in the future [Staecker et al., 2004], much simpler routes like topical drug application onto the cochleostomy opening during surgery – as described in this report – are currently used. Better residual hearing of future EAS candidates, however, demands a simpler, yet more direct route of drug application. Hence, extensive research has focused on the feasibility of intracochlear drug application, which might soon become clinically available.

Conclusions

This paper documents the feasibility of ipsilateral hearing preservation and its long-term stability in about 70% of patients when adequate surgical and medical measures are employed. Complete hearing loss in the acute postoperative setting and progression of initially preserved hearing to complete deafness over time was observed in a small subgroups of patients.

Acknowledgments

The authors wish to thank Dr. Ingeborg Hochmair, Dipl. Ing. Marcus Schmidt, Claude Jolly and the entire clinical research department from MED-EL for their continued effort and their unlimited support for this project. We also would like to thank Blake Wilson, BS, and Dewey Lawson, PhD, for their dedication, expertise, and support. Finally, we would like to acknowledge PD Dr. Martin Mack for his assistance in the radiological aspects of this study.

References

Adunka O, Gstoettner W, Hambek M, et al: Preservation of basal inner ear structures in cochlear implantation. ORL J Otorhinolaryngol Relat Spec 2004a;66:306–312.

Adunka O, Kiefer J, Unkelbach MH, et al: Development and evaluation of an improved cochlear implant electrode design for electric acoustic stimulation. Laryngoscope 2004b; 114:1237–1241.

Adunka O, Pillsbury CH, Kiefer J: Combining perimodiolar electrode placement and atraumatic insertion properties in cochlear implantation – fact or fantasy? Acta Otolaryngol, in press.

Adunka O, Unkelbach MH, Mack M, et al: Cochlear implantation via the round window membrane minimizes trauma to cochlear structures: a histologically controlled insertion study. Acta Otolaryngol 2004c;124: 807–812.

Adunka O, Unkelbach MH, Mack MG, et al: Predicting basal cochlear length for electric-acoustic stimulation. Arch Otolaryngol Head Neck Surg 2005;131:488–492.

Aschendorff A, Klenzner T, Richter B, et al: Evaluation of the HiFocus electrode array with positioner in human temporal bones. J Laryngol Otol 2003;117:527–531.

Briggs RJ, Tykocinski M, Stidham K, et al: Cochleostomy site: implications for electrode placement and hearing preservation. Acta Otolaryngol 2005;125:870–876.

Eshraghi AA, Polak M, He J, et al: Pattern of hearing loss in a rat model of cochlear implantation trauma. Otol Neurotol 2005;26: 442–447; discussion 447.

Gantz BJ, Turner CW: Combining acoustic and electrical hearing. Laryngoscope 2003;113: 1726–1730.

Gantz BJ, Turner C, Gfeller KE, et al: Preservation of hearing in cochlear implant surgery: advantages of combined electrical and acoustical speech processing. Laryngoscope 2005; 115:796–802.

Greenwood DD: A cochlear frequency-position function for several species – 29 years later. J Acoust Soc Am 1990;87:2592–2605.

Greenwood DD: Comparing octaves, frequency ranges, and cochlear-map curvature across species. Hear Res 1996;94:157–162.

Gstoettner WK, Adunka O, Franz P, et al: Perimodiolar electrodes in cochlear implant surgery. Acta Otolaryngol 2001;121:216–219.

Gstoettner W, Kiefer J, Baumgartner WD, et al: Hearing preservation in cochlear implantation for electric acoustic stimulation. Acta Otolaryngol 2004;124:348–352.

Hodges AV, Schloffman J, Balkany T: Conservation of residual hearing with cochlear implantation. Am J Otol 1997;18:179–183.

James C, Albegger K, Battmer R, et al: Preservation of residual hearing with cochlear implantation: how and why. Acta Otolaryngol 2005;125:481–491.

Kiefer J, Gstoettner W, Baumgartner W, et al: Conservation of low-frequency hearing in cochlear implantation. Acta Otolaryngol 2004;124:272–280.

Kiefer J, Pok M, Adunka O, et al: Combined electric and acoustic stimulation of the auditory system: results of a clinical study. Audiol Neurootol 2005;10:134–144.

Lehnhardt E: Intracochlear placement of cochlear implant electrodes in soft surgery technique (in German). HNO 1993;41:356–359.

Paasche G, Bogel L, Leinung M, et al: Substance distribution in a cochlea model using different pump rates for cochlear implant drug delivery electrode prototypes. Hear Res 2006; 212:74–82.

Richter B, Jaekel K, Aschendorff A, et al: Cochlear structures after implantation of a perimodiolar electrode array. Laryngoscope 2001;111:837–843.

Scarpidis U, Madnani D, Shoemaker C, et al: Arrest of apoptosis in auditory neurons: implications for sensorineural preservation in cochlear implantation. Otol Neurotol 2003;24: 409–417.

Skarzynski H, Lorens A, Piotrowska A: A new method of partial deafness treatment. Med Sci Monit 2003;9:CS20–CS24.

Staecker H, Brough DE, Praetorius M, et al: Drug delivery to the inner ear using gene therapy. Otolaryngol Clin North Am 2004;37:1091–1108.

von Ilberg C, Kiefer J, Tillein J, et al: Electric-acoustic stimulation of the auditory system. New technology for severe hearing loss. ORL J Otorhinolaryngol Relat Spec 1999;61:334–340.

Zrunek M, Lischka M, Hochmair-Desoyer I, et al: Dimensions of the scala tympani in relation to the diameters of multichannel electrodes. Arch Otorhinolaryngol 1980;229: 159–165.