Central Line Course

Joanna Grudziak, MD
PGY4
General Surgery

Yaw, roll, and pitch

Rudder, aileron, elevator

Takeoff, flight, landing

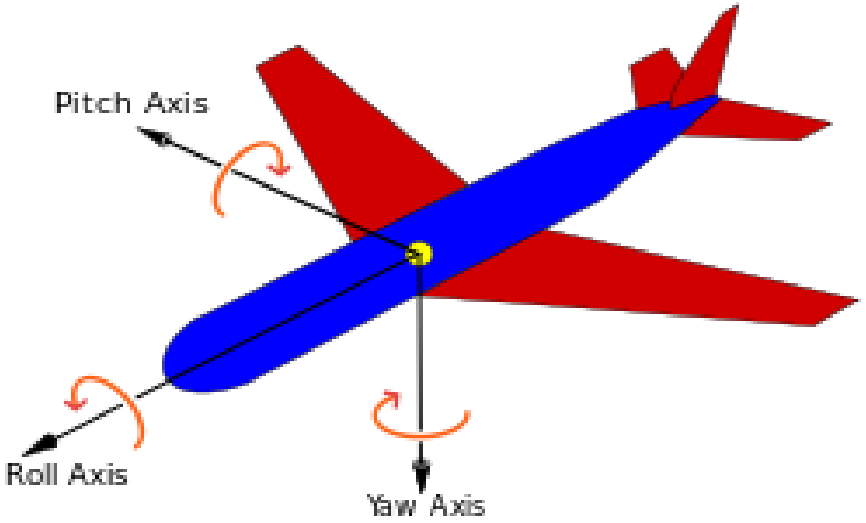

https://en.wikipedia.org/wiki/Aircraft_principal_axes

Background

Central Line placement associated with potential major morbidity:

- Infection
- Arterial injury
- Hemo- and pneumothorax
- Stroke
- Cardiac tamponade

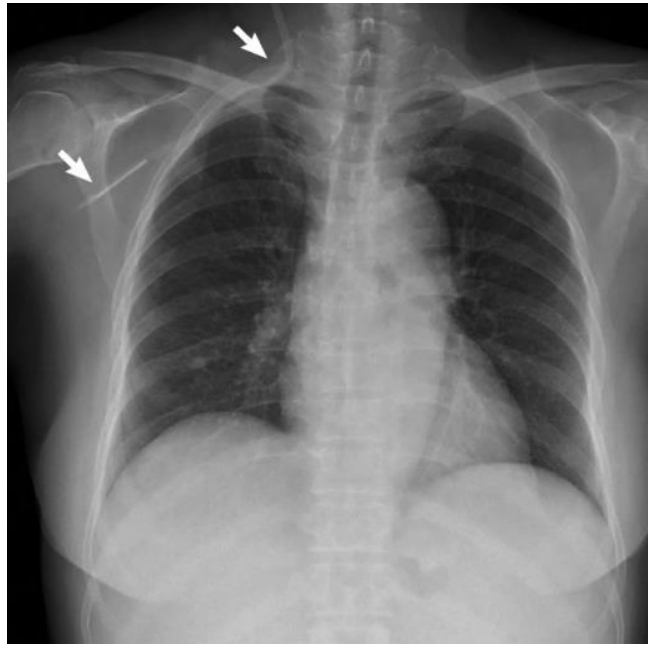

https://openi.nlm.nih.gov/detailedresult.php?img=PMC3468767_jkms-27-1265-g001&req=4

Background

Central line complications related to placement decrease with:

- Clinicians who have performed > 50 line insertions [1]
- Fewer attempts (<3 needle sticks) [1]
- Ultrasound use [2]
- **Simulation-based training for clinicians** [3]

Previously no standardized teaching method for UNC residents

1. Young MP. (2016). Complications of central venous catheters and their prevention. In: UpToDate, Collins KA (Ed), UpToDate, Waltham, MA. (Accessed on May 17, 2016.)
2. McGee DC & Gould MK. (2003). Preventing complications of central venous catheterization. *NEJM, 348*: 1123-1133.
3. Barsuk JH, McGaghie WC, Cohen ER, O'Leary KJ, & Wayne DB. (2009). Simulation-based mastery learning reduces complications during central venous catheter insertion in a medical intensive care unit. *Crit Care Med, 37*(10): 2697-701.

Background

- **Inaugural Multidisciplinary M&M** – June 2014
  - Resident-led
  - Central line complication resulting in vascular surgery intervention

- **Resident Task Force** formed with assistance from faculty across five departments:
  - Anesthesia
  - Emergency Medicine
  - Family Medicine
  - Internal Medicine
  - Surgery

Why?

Project Aim

To develop and implement a standardized central line placement training for all interns with opportunity to insert central lines


We accidentally replaced your heart
with a baked potato.

Intern Central Line Training Course

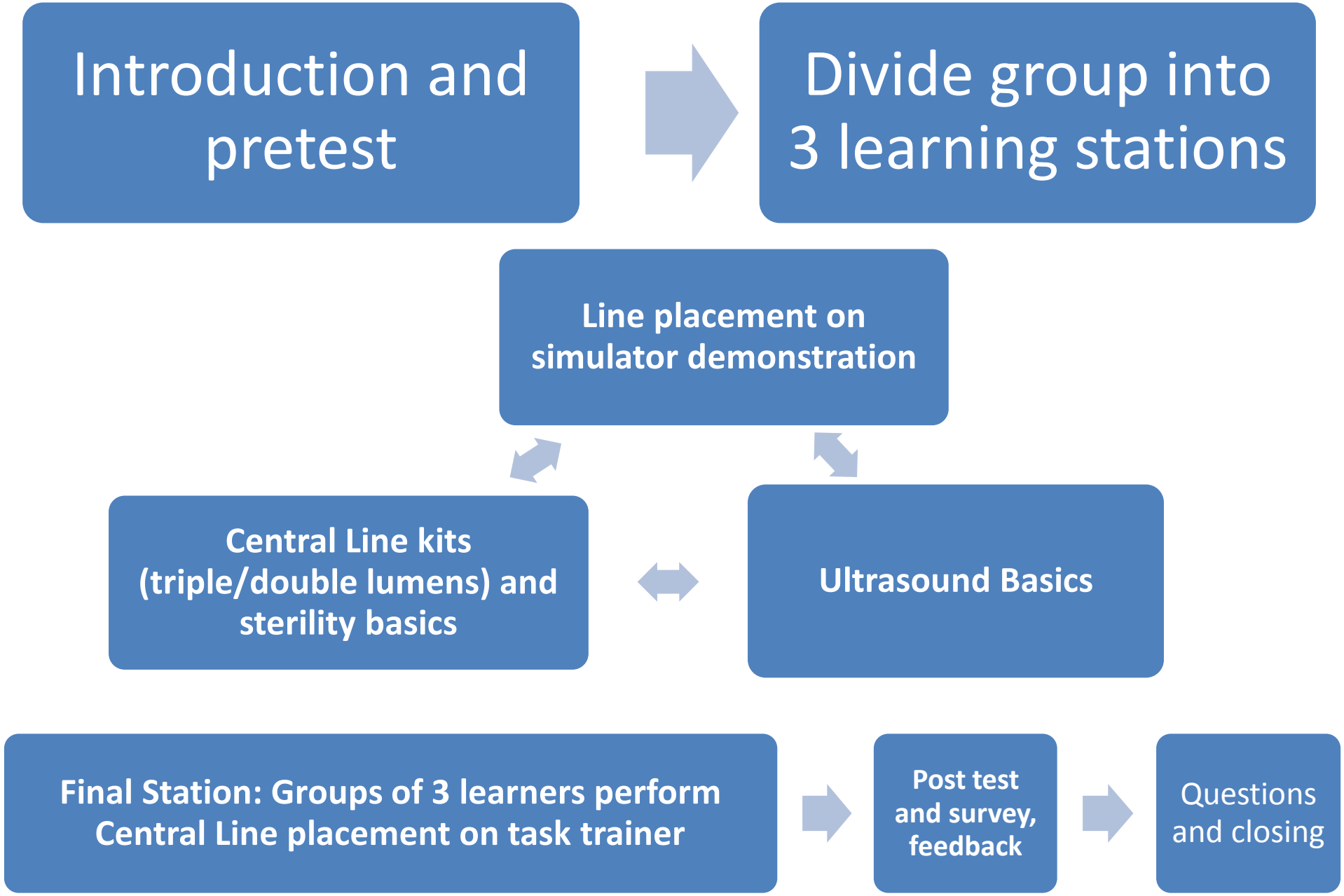

Sterile Technique and Kit Familiarization

Vascular ultrasonography

Teaching interns how to use ultrasound to determine site for central line placement

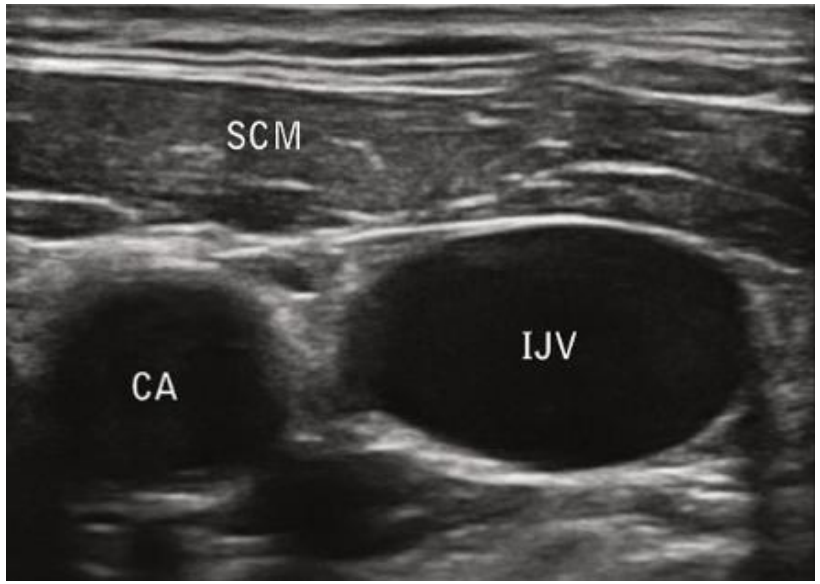

http://www.ultrasonix.com/blog/internal-jugular-vein-vascular-access-line-placement

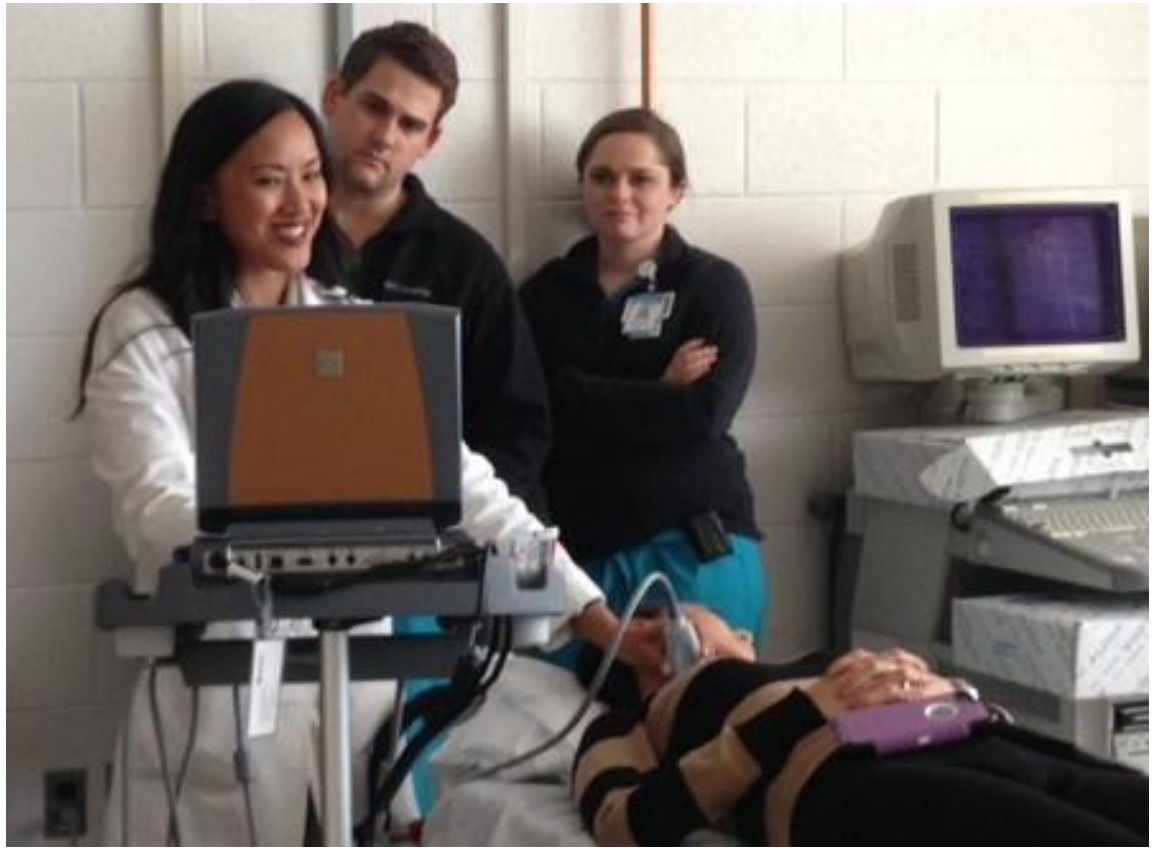

Line Placement on Simulators

CLeAR lab designed and built custom-made simulator

- perfused, ultrasound-compatible neck model
- pressurized liquid mimics arterial/venous pressures
- capable of multiple sticks without wear and tear
- very affordable compared to market alternatives ($5K for 3 vs $6K for 1)

Line Placement – Instructor Example

Individual Line Placement by Interns

Numbers Trained

Interns Trained

- **99 interns in 11 classes**
  - Anesthesia – 12
  - Emergency Medicine – 10
  - Family Medicine – 10
  - Internal Medicine – 35
  - Surgery – 29
  - Also, 3 from Neuro

Instructors Trained/Scheduled

- **12 instructors in 4 "Train the Trainer" classes**

Pre and Post-Test Scores

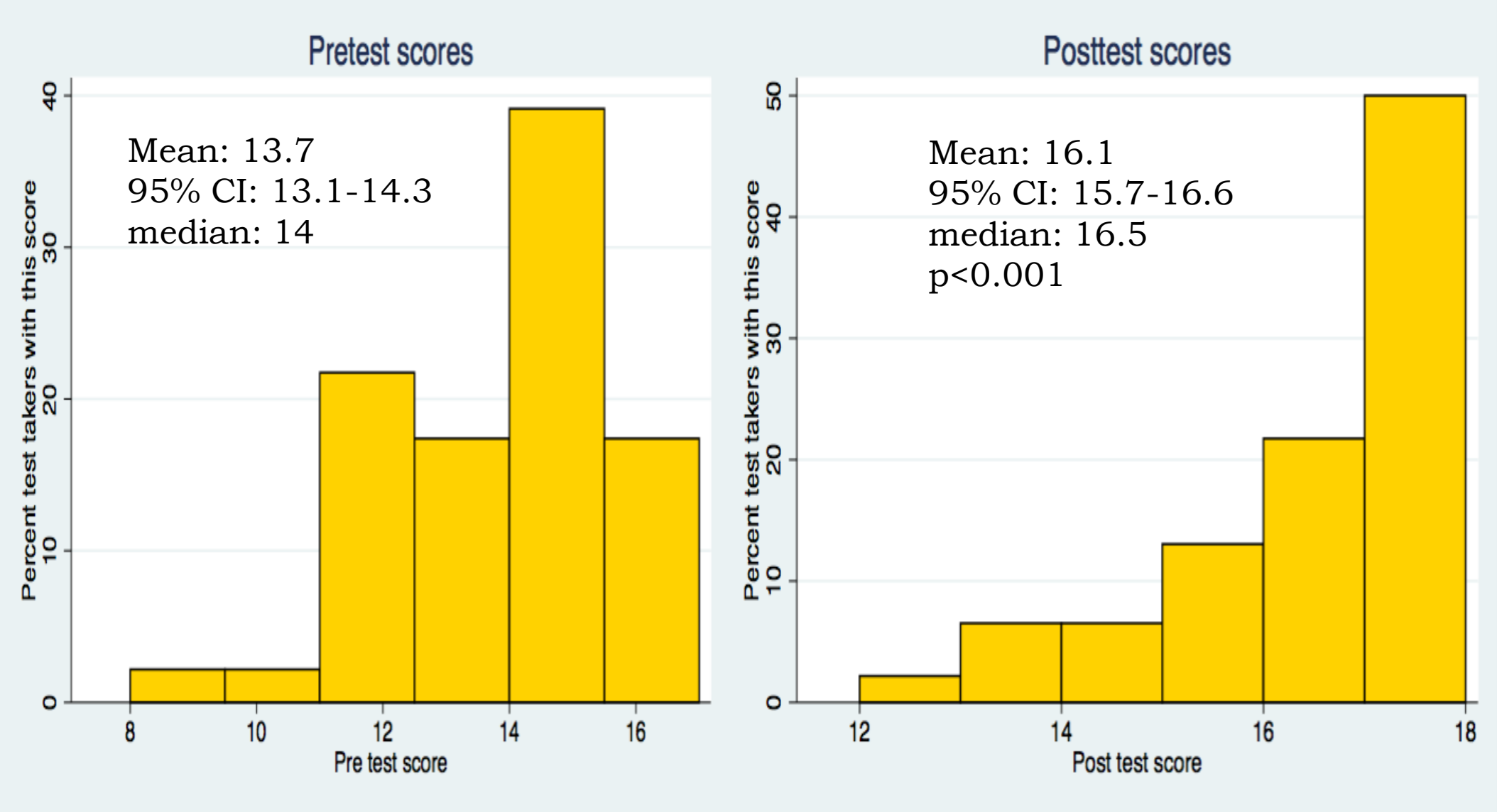

Intern Comfort with Use of Ultrasound

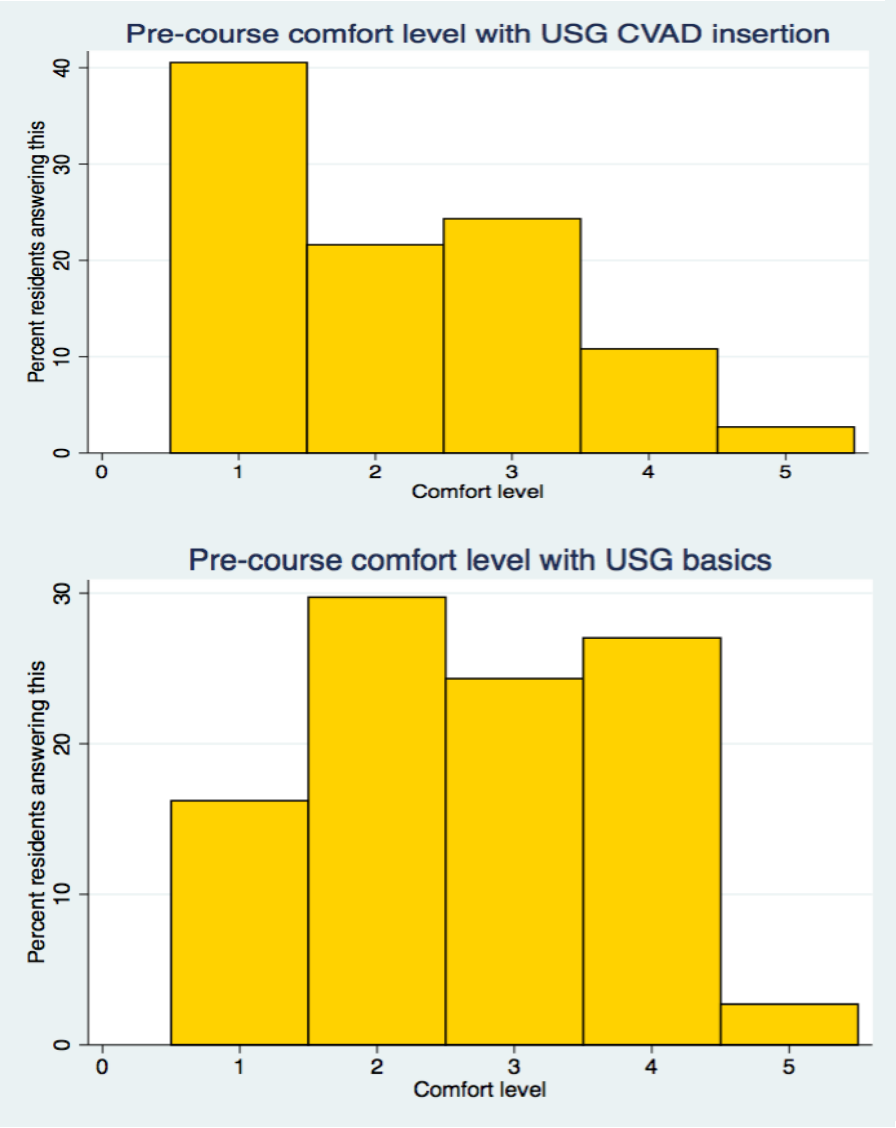

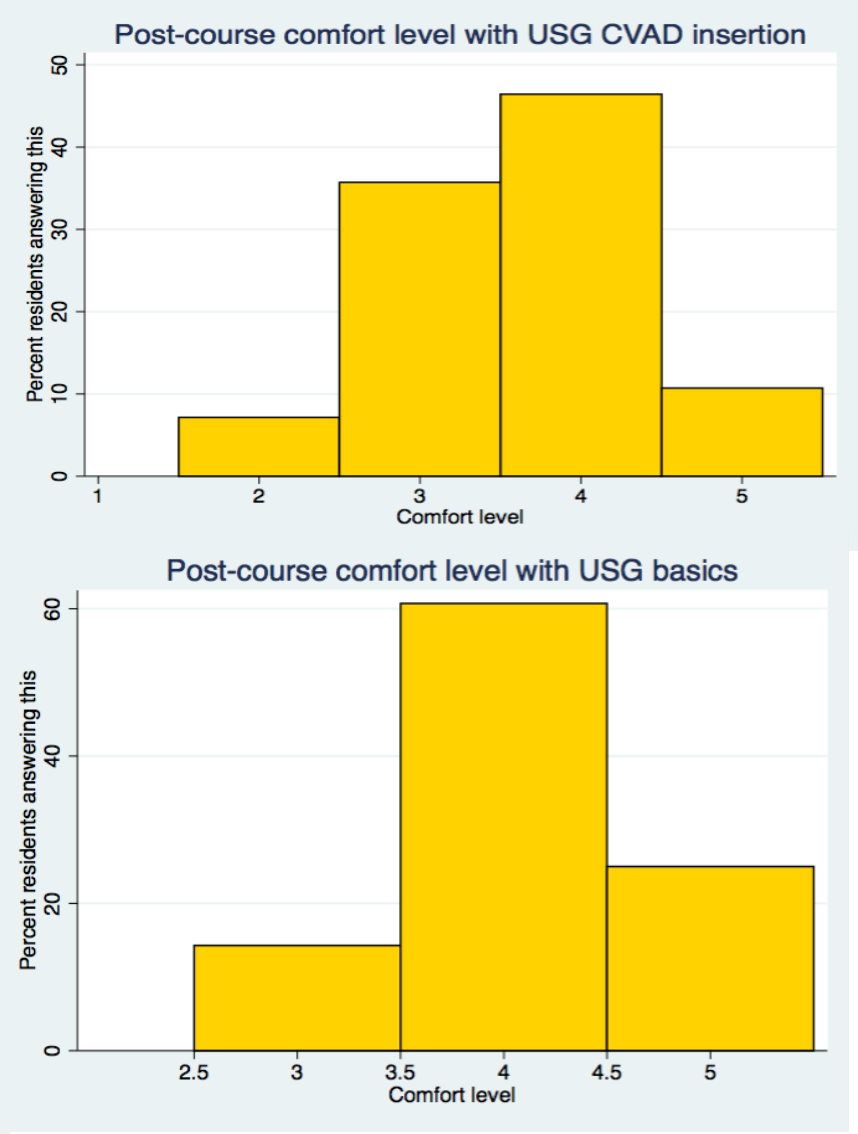

Comfort increased for line placement with ultrasound, from **2.29** +/- 1.18 to **3.61** +/-0.79, p<0.001

Comfort increased for ultrasound basics, from **2.70** +/- 1.13 to **4.10** +/- 0.6, p<0.001

Intern Perspective

- Thank you very much – this was a great experience!
- This was very helpful – I feel better prepared and more knowledgeable.
- **Thank you for taking the time to go over this early in our training.**
- This was a great training. Maybe we could do this twice during our intern year.
- This was an excellent course. Even though I've had some experience with lines before, I found this very helpful.[I liked] getting to handle the line kit and get more ultrasound experience.

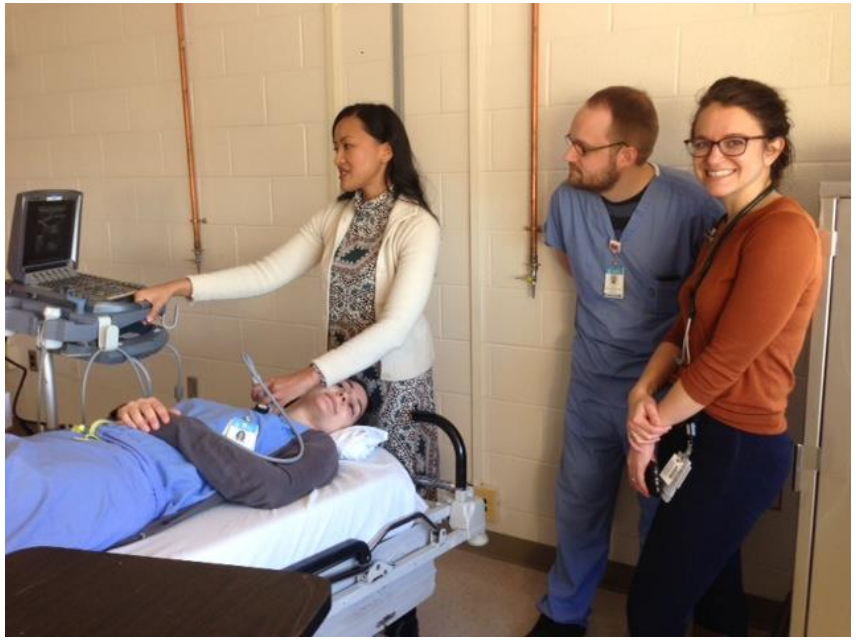

Sustainability Plan

- GME to take over administration of central line course for 2016-17 and beyond
- Data collection continuing
- Central Line Video
  - Filmed this spring
  - Will be used for future classes

- **Outstanding issues**:
  - protected time for faculty
  - simulation home
  - budget for supplies beyond coming year
  - resources for continued data collection

Dissemination Plan

- Multidisciplinary M&M
  - *UNC, Sept. 2015*
- International Meeting for Simulation & Health Care
  - *San Diego, Jan. 2016*
- House Staff Council Meeting
  - *UNC, Feb. 2016*
- Southeastern Surgical Congress
  - *Atlanta, Feb. 2016*
- American Surgeon (publication pending)
- NC American College of Physicians meeting
  - *Greensboro, Feb. 2016*
- Surgery Grand Rounds
  - *UNC, Jun. 2016*



Lessons Learned

"Nobody argues with a flight simulator"
-Tina Willis, MD

- **Power of and challenges in interdisciplinary collaboration**

- Learning from mistakes
  - Original simulators
  - Teaching suturing

- The blood, sweat, and tears of data collection

- **Structural support essential**

- Importance of residents driving improvement

- Persistence key to sustainability

1. Before routine insertion of a central venous catheter all of the following steps must be done EXCEPT?

☐ Obtain consent from the patient or their family or guardian etc.
☐ Perform a site survey with the ultrasound to ensure the vessel is present and patent.
☐ Cleanse the skin with chlorhexidine (if the patient is not allergic) and allow to dry.
☐ Use maximal barrier precautions, including hat, mask, gloves, sterile gown and sterile full body drape.
☐ Call your attorney.

2. Ultrasound guidance decreases mechanical AND infectious complications of central line infection.

☐ True
☐ False

3. The best probe for vascular access guidance is

☐ A HIGH frequency probe a with a FLAT footprint
☐ A LOW frequency probe a with a FLAT footprint
☐ A HIGH frequency probe a with a CURVED footprint
☐ A LOW frequency probe a with a CURVED footprint
☐ A phased array probe

4. Which of the statements below is CORRECT regarding ultrasound guided vascular access? (single best answer)

☐ Using ultrasound only to identify landmarks without visualizing needle entry is just as safe and effective as using ultrasound throughout needle entry
☐ Ultrasound decreases the complication rate with central venous access.
☐ A written note is sufficient documentation of ultrasound guided vascular access, no images need to be saved or printed for billing or QA purposes
☐ It is unnecessary to put sterile gel inside and outside the probe cover sleeve for ultrasound guided venous access

5. Antiseptic disk (BioPatch) at the skin puncture site is required for central lines at UNC.

☐ True
☐ False

6. This image of a central venous access procedure shows:

☐ The jugular vein is about 2.2 cm deep according to the depth scale
☐ The needle has penetrated the carotid artery
☐ An "in-plane" or "along-the-needle view"
☐ A non-compressible internal jugular vein due to intraluminal clot

7. Which of the following are possible complications of a central line insertion?

☐ Pneumothorax.
☐ Wire or catheter embolization.
☐ Stroke (cerebrovascular accident).
☐ Air embolism.
☐ Arrhythmia including ventricular tachycardia or fibrillation.
☐ All of the above.

8. Ultrasound guidance for central venous line insertion has been shown to do all of the following EXCEPT?

☐ Reduces infectious risk
☐ Reduces number of attempts to successfully place catheter
☐ Reduces time required for inserting the central line
☐ Reduces number of assistants needed for the procedure

9. Betadine is preferred over chlorhexidine for skin antisepsis:

☐ True
☐ False

10. When advancing the catheter into the vein with the Seldinger wire, it is critical that the catheter is slid over the wire, and the wire and catheter are not advanced together

☐ True
☐ False

11. Blood return into the syringe can occur while the needle is being withdrawn instead of being advanced.

☐ True
☐ False

12. Medicare and many insurers will not pay for for infections and pneumothoraces associated with central venous catheter placement (CLABSI).

☐ True
☐ False

13. After applying the chlorhexidine to the insertion site, one should wait until the site is completely dry without fanning or blotting before proceeding.

☐ True
☐ False

14. Regarding central line insertions: (single correct answer)

☐ Pneumothorax is not a hazard of the internal jugular approach.
☐ The internal jugular vein is accessible by a needle inserted at the level of C6 aimed towards the contralateral nipple.
☐ A chest X-ray is unnecessary to confirm central line placement if the ultrasound documents the line inside the vein.
☐ When using 2D mode with the ultrasound, the lumen of vessels should appear dark.

15. This arrow in image below is showing: (single best answer)

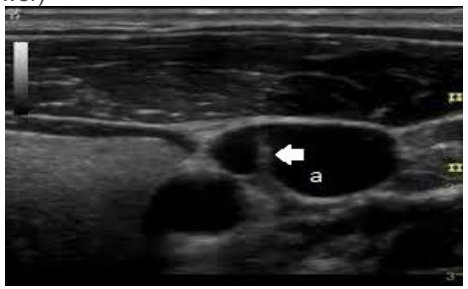

☐ Needle seen in the internal jugular vein in an “in-plane” approach
☐ Needle seen in the internal jugular vein in an “out of plane” approach
☐ Needle seen in the carotid artery in an “in-plane” approach
☐ Needle seen in the carotid artery in an “out of plane” approach

16. The correct way to sterilize skin with chlorhexidine is to (single answer)

☐ Use a scrubbing motion for at least 30 seconds
☐ Cleanse the skin in a concentric circular pattern
☐ Use at least 2 swabs/sticks

17. Use of a checklist to adhere to infection-control practices as part of a central line bundle has decreased CLABSI rates in prospective trials.

☐ True
☐ False

18. The following practices help ensure that the carotid artery (CA) is not injured during central line placement: (single answer)

☐ Choosing a site in which the CA is just deep to the internal jugular vein.
☐ Using manometry to estimate the pressure in the vessel before dilating.
☐ Viewing the guidewire in the vessel in the short axis, out-of-plane view before dilating

Special thanks to the UC San Diego School of Medicine SICU Central Line Course for some of our test questions