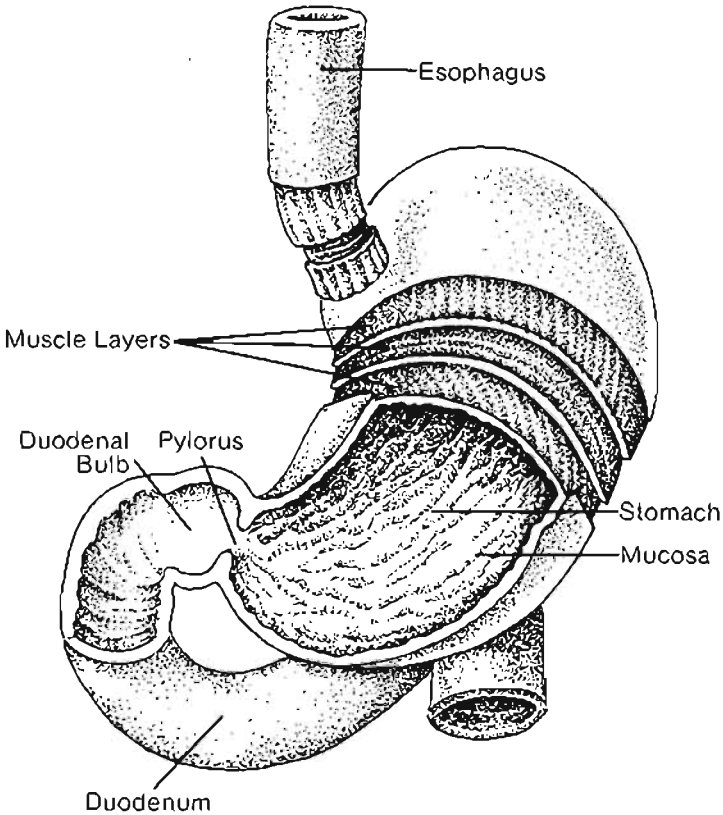
Esophagus
Muscle Layers
Duodenal Bulb
Pylorus
Stomach
Mucosa
Duodenum

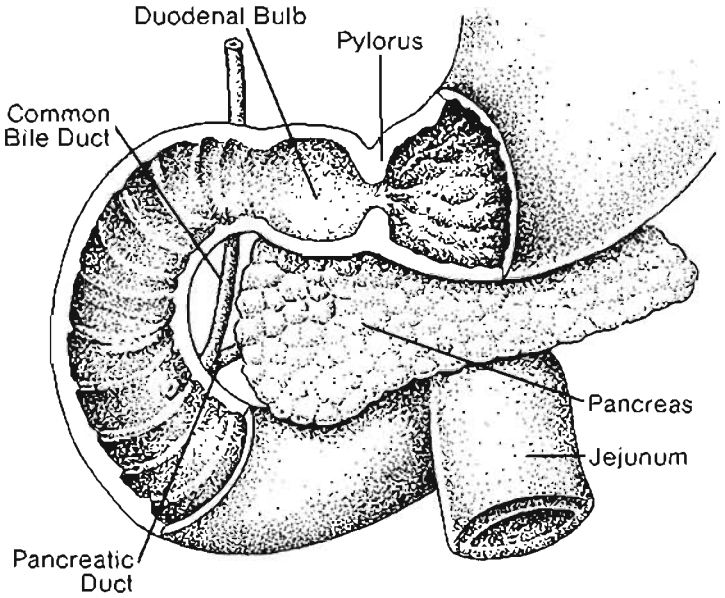
Duodenal Bulb
Pylorus
Common Bile Duct
Pancreas
Jejunum
Pancreatic Duct

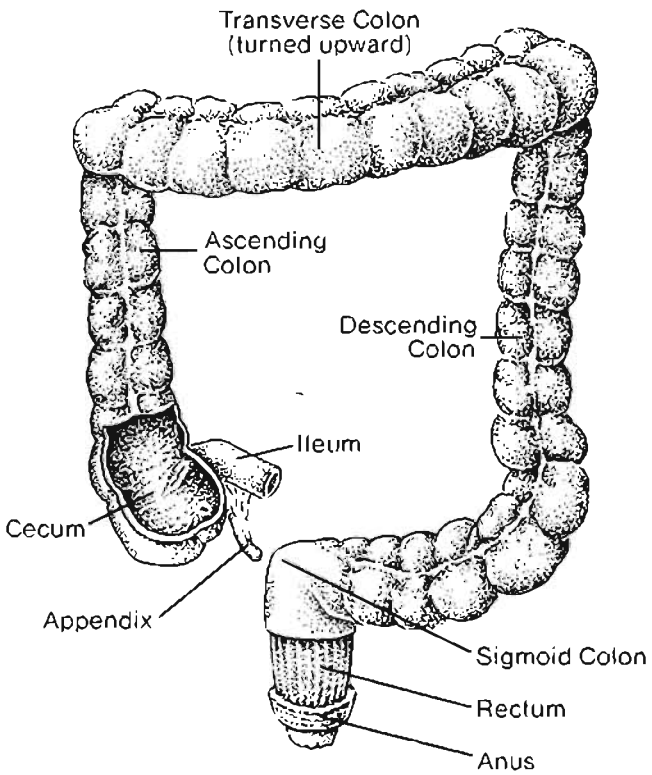
Transverse Colon (turned upward)
Ascending Colon
Descending Colon
Ileum
Cecum
Appendix
Sigmoid Colon
Rectum
Anus

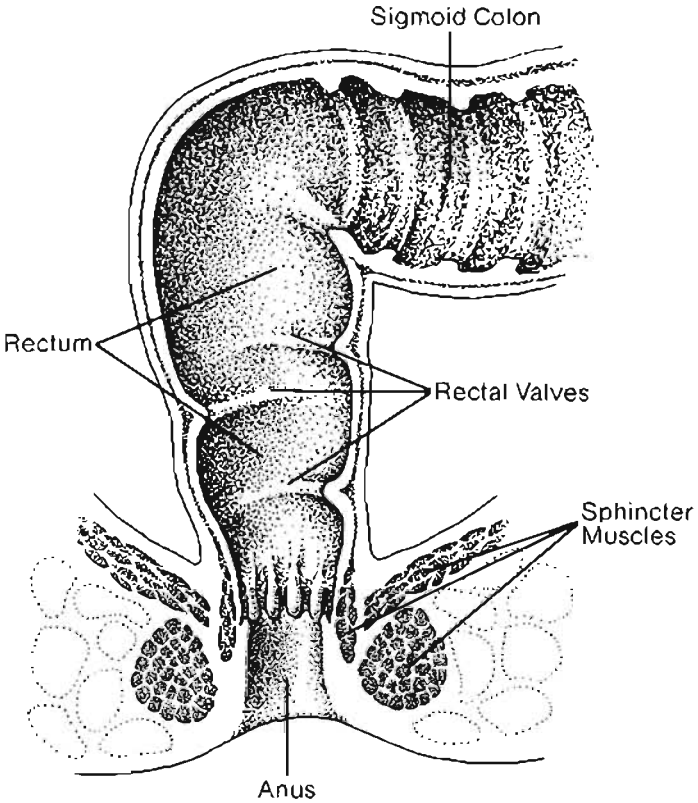
Sigmoid Colon
Rectum
Rectal Valves
Sphincter Muscles
Anus