An Uncommon Presentation of the Common Cold: Pyelonephritis in an Immunocompromised Patient

Emily J. Ciccone, MD, MHS and John R. Stephens, MD

Departments of Internal Medicine and Pediatrics
University of North Carolina School of Medicine, Chapel Hill, NC

Take Home Points

- In the setting of immunosuppression, a wide range of infectious etiologies for urinary tract infections, including adenovirus, should be considered early in the evaluation to minimize morbidity and mortality.
- Adenovirus infection in solid organ transplant patients most frequently manifests as hemorrhagic cystitis but can also cause disseminated disease.

Case Presentation

- A 30-year-old woman with a history of renal transplant in 2014 for lupus nephritis presented with ten days of painful urination, abdominal pain over her transplanted kidney, and hematuria.
- Despite initiating treatment with ciprofloxacin on day three of illness, her symptoms did not resolve and she went on to develop chills, headache, and fever.
- She reported compliance with her immunosuppression regimen including prednisone, mycophenolate mofetil and tacrolimus.
- Initial exam was significant for fever, tachycardia, hypotension, suprapubic tenderness, and pain with palpation of transplanted kidney.
- She was started on intravenous fluids, vancomycin and cefepime, but remained persistently febrile over the next 48 hours.

Hospital Course

Initial Laboratory Studies	
Urinalysis	+Leukocyte esterase, >182 WBC, >182 RBC
Complete Blood Count	WBC 5.2, Hgb 11.2, Plt 263, ANC 3.7, ALC 0.9
Kidney Function	Creatinine 1.62 (baseline 0.7-0.8), BUN 20
Blood Cultures (x2)	Negative
Urine Culture	Mixed urogenital flora

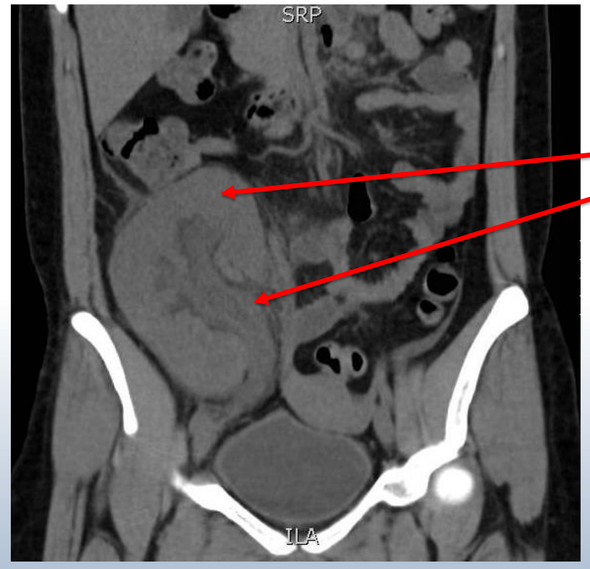

Non-contrast CT scan of the abdomen/pelvis was consistent with pyelonephritis:
- Moderate hydroureteronephrosis
- Thickened urothelium
- No nephrolithiasis or perinephric abscess.

Serum BK virus PCR	Negative
Serum CMV PCR	Negative
Serum Adenovirus PCR	**Positive**
Urine Adenovirus PCR	**Positive**
Stool Adenovirus PCR	**Positive**

She was treated with cidofovir and probenicid. Mycophenolate was discontinued. Both urine and blood adenovirus PCR remained positive on hospital day eight, so she was transitioned to oral brincidofovir and discharged home. At her follow-up visit 3 weeks later, adenovirus testing was negative.

Discussion

- Our patient presented with classic symptoms of pyelonephritis but was found to have disseminated adenovirus infection.
- Disseminated disease is defined as involvement of two or more organs not including viremia.
- Outcomes range from rapid clearing of the virus with recovery of graft function to graft failure and death.
- Treatment includes reduction of immunosuppression and antiviral therapy with cidofovir, administered with probenecid and hydration to prevent nephrotoxicity.
- A novel orally bioavailable, lipid conjugate form of cidofovir, called brincidofovir, has been developed and, in preliminary studies, has not been associated with nephrotoxicity.

References

Sandkovsky U, Vargas L, Florescu DF. Adenovirus: current epidemiology and emerging approaches to prevention and treatment. Curr Infect Dis Rep. 2014 Aug;16(8):416.

Sujeet K, Vasudev B, Desai P, Bellizzi J, Novoa-Takara L, He C, et al. Acute kidney injury requiring dialysis secondary to adenovirus nephritis in renal transplant recipient. Transpl Infect Dis. 2011 Apr;13(2):174–7.