

Regional and Lobe Parcellation Rhesus Monkey Brain

Atlas

Manual Tracing for Parcellation Template

Overview of Tracing Guidelines

- A) Traces are performed in a systematic order they, allowing the more easily defined regions to provide borders for the more difficult regions. The order of parcellation is as follows:
1. Corpus callosum
 2. Cingulate gyrus
 3. Insula
 4. Cerebellum
 5. Subcortical exclusion area
 6. Medulla and Pons
 7. Prefrontal lobe
 8. Frontal lobe
 9. Occipital lobe
 10. Temporal lobe: Limbic
 11. Temporal lobe: Auditory
 12. Temporal lobe: Visual
 13. Parietal lobe
- B) Many parts of the protocol instruct the user to trace to or from the “depth” of a sulcus. The “depth” of a sulcus refers to the gray matter/white matter border within the sulcus.
- C) Tracing is done in a combination of the three orthogonal planes, as specified in the detailed methods that follow.
- E) Each region of interest was originally defined in the right hemisphere. The labels were then reflected onto the left hemisphere and all borders checked and adjusted manually when necessary.
- D) For the initial parcellation, the user used the “paint over function” of IRIS/SNAP painting over label 1 and label 2 (GM and WM) of the hard tissue segmentation. The resulting labels were then dilated to fill the entire brain space.

I. Corpus Callosum

Major boundaries

The corpus callosum (CC) is bounded at its superior, anterior and posterior boundaries by the callosal sulcus and the cingulate gyrus. The lateral ventricle forms most of the inferior boundary. The mid-sagittal plane forms the medial boundary.

Anterior to the knee of the cingulate sulcus (where it emits the marginal ramus), the lateral boundary is traced as a straight line between the cingulate sulcus and the lateral-superior corner of the caudate nucleus or lateral ventricle. Posterior to the knee of the cingulate sulcus, the lateral boundary is traced as a straight line between the callosal sulcus and the lateral-superior corner of the caudate nucleus or lateral ventricle. See figure I: corpus callosum

Tracing

- A) Begin in the sagittal plane, working medial to lateral.
 - 1) Identify and label the CC, using the callosal sulcus and cingulate gyrus as the superior boundary, and the ventricle as the inferior boundary.
 - 2) Continue laterally until these boundaries are no longer clearly visible in the sagittal plane.
- B) Switch to the coronal plane to define the lateral boundary of the CC. Work from anterior to posterior.
 - 1) Complete the lateral extent of the corpus callosum. On slices anterior to the knee of the cingulate sulcus, draw a straight line between the cingulate sulcus and lateral-superior corner of the caudate or ventricle, whichever is visible. On slices posterior to the knee of the cingulate sulcus, draw a straight line between the callosal sulcus and lateral-superior corner of the caudate or ventricle, whichever is visible.
- C) Use the axial plane to review and perform additional tracing of boundaries not clearly visible in the previous views. Work from superior to inferior.
 - 1) Review and edit the lateral boundary where necessary.
 - 2) Determine inferior and posterior boundaries at the lateral extent. Follow the narrow extensions of CC back to the ventricle, until the CC becomes very narrow, and then follow the distinct WM boundary of the CC.

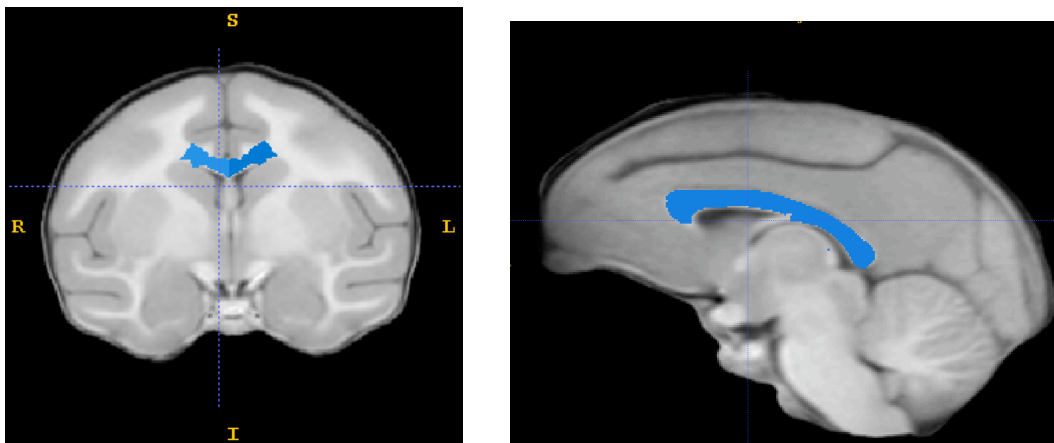


Figure I. Corpus Callosum

Completed corpus callosum trace (blue) seen in the coronal (left) and sagittal (right) views.

II. Cingulate Gyrus

Major boundaries:

The cingulate gyrus is bounded at its anterior and superior extents by the cingulate sulcus, at its inferior extent by the callosal sulcus and corpus callosum, and at its medial extent by the interhemispheric fissure. Anterior to the knee of the cingulate sulcus (where it emits the marginal ramus), the lateral boundary is traced as a straight line across the WM, connecting the depths of the cingulate and callosal sulci. Posterior to the knee of the cingulate sulcus, the lateral boundary is traced as a straight line connecting the splenial sulcus to the tip of the lateral ventricle. The posterior boundary is the splenial sulcus. See figure II: Cingulate.

Tracing:

A) The cingulate sulcus is first marked in the sagittal plane.

- 1) Identify and trace the cingulate gyrus on the first 5 slices lateral to the inter-hemispheric fissure. The anterior boundary is the cingulate sulcus. Anterior to the knee of the cingulate sulcus, the superior boundary is the cingulate sulcus. Posterior to the knee of the cingulate sulcus, the superior boundary is the splenial sulcus. The posterior boundary is the splenial sulcus. The inferior boundary is the callosal sulcus. The cingulate gyrus curves under the corpus callosum at the front and back.

B) Switch to the coronal plane, in which most of the tracing is performed.

- 1) Begin at the most anterior coronal slice containing cingulate label from the sagittal plane. Work from anterior to posterior.
- 2) Trace the cingulate gyrus, following cingulate and callosal sulci as marked. Cut across the WM between depths of cingulate and callosal sulci to draw the lateral boundary.
- 3) Interhemispheric fissure is the medial boundary.
- 4) Continue until you reach the knee of the cingulate sulcus where it emits the marginal ramus.
- 5) Now, use the cingulate label from the sagittal plan as the superior boundary. Draw a straight line from the superior and lateral extent of the existing label, across the WM, to the tip of the lateral ventricle.

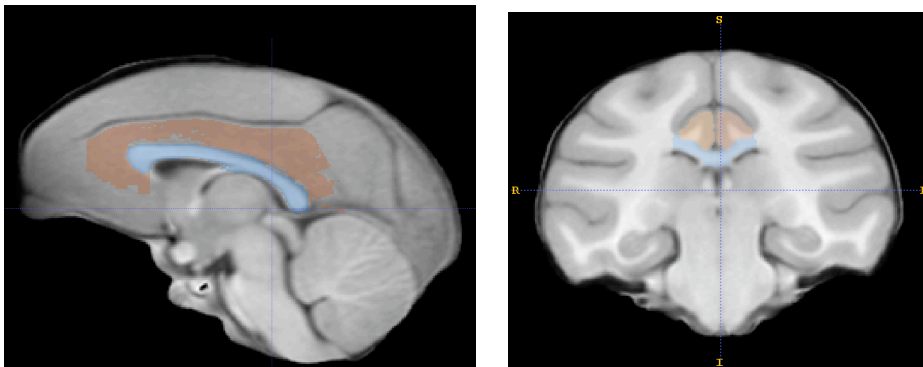


Figure II: Cingulate

Completed cingulate trace (brown) seen in sagittal (left) and coronal (right) views

III. Insula

Major boundaries:

The insula consists of the gray matter in the depth of the Sylvian Fissure. The superior, inferior, anterior, and posterior boundaries of the insula are traced at the center of the insular sulcus. The lateral boundary is CSF within the Sylvian Fissure. The medial boundary is the lateral edge of extreme or external capsule. See figure III: Insula.

Tracing:

A) Begin in the axial view, working from superior to inferior.

- 1) Label the GM within the depth of the Sylvian Fissure.
- 2) The CSF within the Sylvian Fissure is the lateral boundary.
- 3) The lateral edge of the extreme or external capsule (whichever is visible) is the medial boundary.
- 4) The center of the insular sulcus forms all other boundaries.

B) In the coronal view, work from posterior to anterior. Review and complete trace, using same boundaries as used in the axial plane.

C) Use the sagittal view to check trace, working from lateral to medial.

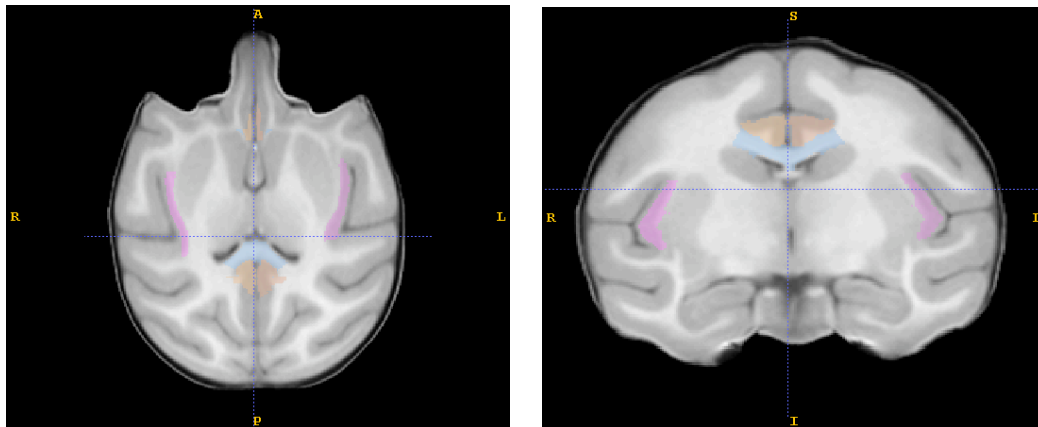


Figure III: Insula

Completed insula trace (pink) in axial (left) and coronal (right) views.

IV. Cerebellum:

Major boundaries: Surrounding CSF forms the posterior, inferior, and lateral boundaries of the cerebellum. The superior boundary is the inferior extent of the cerebrum. The medial boundary is the midline slice of the cerebellum. The boundary between the cerebellum and brainstem is the point where the cerebellar peduncles join with the brainstem. The boundary with the middle cerebellar peduncles is traced in the axial view by drawing a straight line between Cranial Nerve V and the notch of the fourth ventricle. Cerebellar peduncles are included with the cerebellum. See figure IV: Cerebellum.

Tracing:

- A) The cerebellum is mostly traced in the sagittal view, working medial to lateral.
- 1) Begin at the cerebellum mid-sagittal slice. Keep in mind that cerebellum mid-sagittal may not be the same as cerebrum mid-sagittal.
 - 2) Trace the cerebellum, using the surrounding CSF and cerebrum as boundaries.
 - 3) The anterior boundary at the level of the superior cerebellar peduncles is defined as the posterior extent of the pons. That is, slice the superior cerebellar peduncles flush with the pons.
 - 4) Continue tracing in the sagittal view to the lateral extent of the cerebellum.
- B) Switch to the axial view to trace the boundary with the brainstem.
- 1) At the level of the middle cerebellar peduncle trace a straight line between Cranial Nerve V and the lateral corner of the 4th ventricle to form the boundary between penduncle and pons.

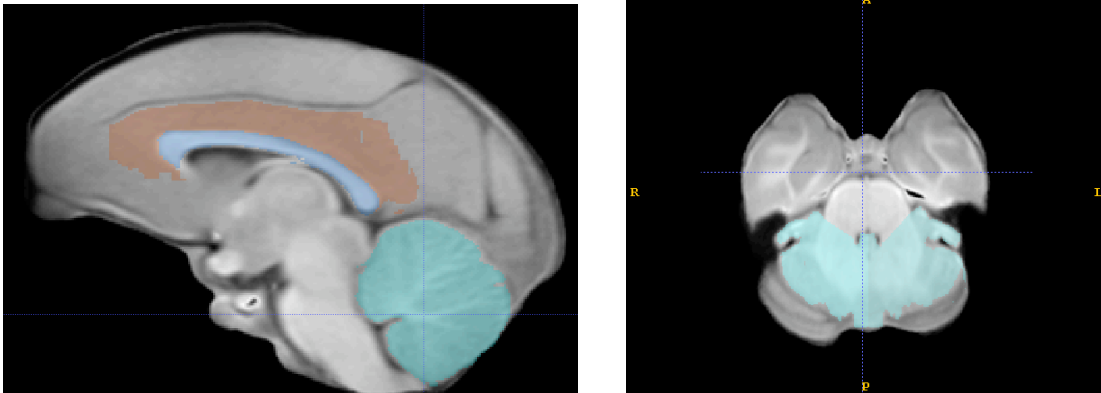


Figure IV: Cerebellum

Completed Cerebellum trace (aqua) in sagittal (left) and coronal (right) views

V. Subcortical Area:

Major boundaries:

This region is traced as a group for the purpose of exclusion from the other regions. It is not intended to measure individual subcortical structures. The following areas are traced as part of the subcortical exclusion area: caudate, thalamus, putamen, globus pallidus, internal, external and extreme capsules, and ventricles within this region. In general, the trace follows the “external” boundaries of the caudate, external or extreme capsule, and the thalamus. The superior and posterior boundaries are the callosal sulcus, the anterior boundary is the extent of the caudate nucleus, the inferior boundary is top of the middle cerebellar peduncles. Where cutting across white matter at the superior extent of the internal capsule, a straight line is drawn from the corner of the corpus callosum trace, to the corner of the putamen, and then across the external capsule to the insula trace. See figure V: subcortical.

Tracing:

- A) The subcortical area is first identified and traced in the sagittal plane. Begin at the mid-sagittal slice and work medial to lateral.
- 1) The CC label is the superior boundary.
 - 2) CSF at the extent of the brainstem defines the anterior and posterior boundaries.
 - 3) The inferior boundary with the brainstem is at the inferior extent of the cerebellum.
 - 4) In more lateral slices, boundaries change slightly:
 - a. The cerebellum trace defines the boundary with the cerebellar peduncles.
 - b. The caudate nucleus defines the anterior boundary.
 - 5) Stop tracing in the sagittal view when the CC label is no longer present.
- B) Switch to the coronal plane, in which most of the tracing is performed.
- 1) Begin on the most anterior slice containing subcortical trace from the sagittal plane. Work from anterior to posterior.
 - 2) Make sure all of the caudate, putamen, globus pallidus and nucleus accumbens are included with the trace.
 - 3) Cut across the WM of the internal capsule by drawing a straight line from the CC label to the superior corner of the putamen and straight across the external capsule to the insula label.
 - 4) For most of the coronal slices, the CC forms the superior boundary and the insula label forms the lateral boundary. The inferior boundary is the pons, which is marked by the superior extent of the bulging middle cerebellar peduncles.
 - 5) Do not include the amygdala and hippocampus; they will be traced with the temporal lobe.
- C) Use the axial plane to review and perform additional tracing of boundaries not clearly visible in the previous views.
- 1) Work from superior to inferior, reviewing existing trace and editing where necessary. Follow the same general boundaries as in the coronal view.
 - 2) The posterior-lateral boundary is a straight line across the WM and ventricle, connecting the insula and CC traces.

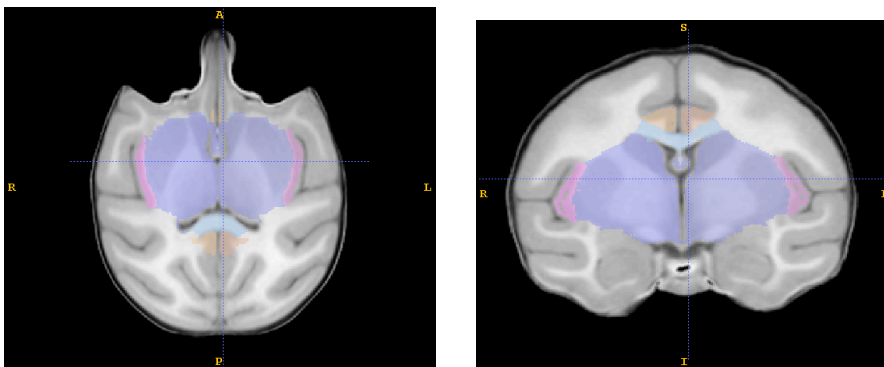


Figure V: Subcortical Area

Completed subcortical trace (dark blue) in axial (left) and coronal (right) views.

VI. Medulla and Pons (Brainstem)

Major Boundaries:

The superior boundary is the subcortical exclusion area trace; the anterior boundary is CSF; the posterior boundary is CSF or the cerebellar trace; the inferior boundary is the beginning of the spinal cord (just inferior to the inferior extent of the cerebellum). See Figure VI: Medulla and pons.

A) The medulla and pons are identified and traced in the sagittal view. Begin at the mid-sagittal slice and work medial to lateral.

- 1) The superior boundary is the subcortical exclusion area
- 2) The anterior boundary is CSF
- 3) The posterior boundary is CSF or the existing cerebellar trace.
- 4) The inferior boundary is the beginning of the spinal cord (just inferior to the inferior extent of the cerebellum). **Ask martin how he decided where to cut brainstem.**

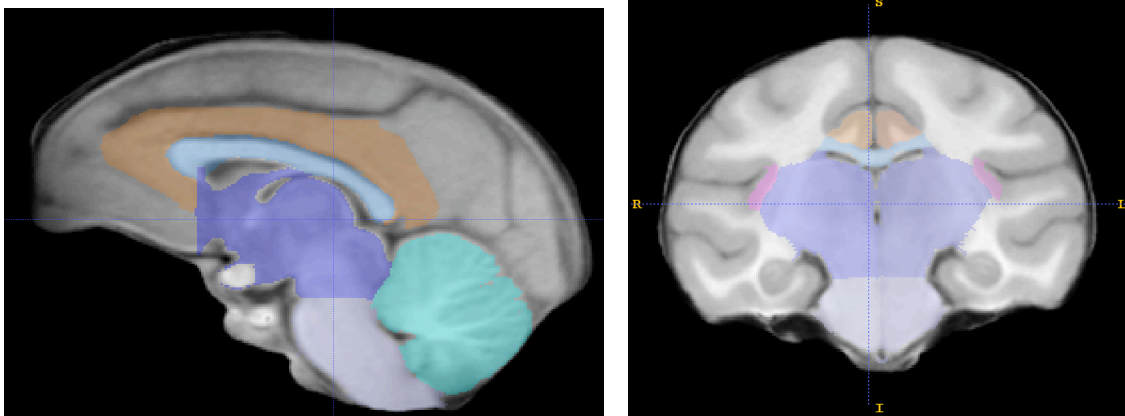


Figure VI: Medulla and Pons

Completed Medulla and Pons trace (lilac) in sagittal (left) and coronal (right) views

VII. Prefrontal Lobe:

Major boundaries:

The prefrontal lobe is bounded at its anterior and lateral extents by CSF at the surface of the brain. The medial boundary is the interhemispheric fissure and existing traces of interior structures. The superior boundary is CSF in the anterior portions and then the arcuate sulcus. The posterior boundary is the arcuate sulcus. The inferior boundary is CSF in the anterior portions, then the Sylvian Fissure, and then the arcuate sulcus. See Figure VII: Prefrontal Lobe.

Tracing:

A) Mark the arcuate sulcus in the sagittal view.

- 1) Use the sagittal view, working medial to lateral, to mark the arcuate sulcus.
 - a) mark the arcuate sulcus by labeling the anterior bank of the sulcus in each slice.

B) Switch to the coronal view to do the majority of the tracing. Work from anterior to posterior.

- 1) In the most anterior slices (before the arcuate sulcus appears), all brain tissue is prefrontal. The interhemispheric fissure is the medial border. CSF at the extent of the brain forms all other boundaries.
- 2) As the traces at the interior of the brain appear, label all remaining tissue as frontal lobe. When the temporal poles appear, the Sylvian fissure is the boundary between the prefrontal and temporal lobes.
- 3) When the arcuate sulcus appears (as previously marked), a superior and inferior branch will be visible. Label all non-labeled tissue between the 2 branches of the arcuate sulcus as prefrontal.
 - a) A straight line across the WM from the depth of the inferior arcuate sulcus to the inferior-medial extent of the brain defines the inferior boundary between the prefrontal and frontal lobes.
 - b) A straight line across the WM from the depth of the superior arcuate sulcus to the inferior corner of the CC label defines the superior boundary between the prefrontal and frontal lobes.
- 4) The posterior boundary is the posterior extent of the arcuate sulcus.

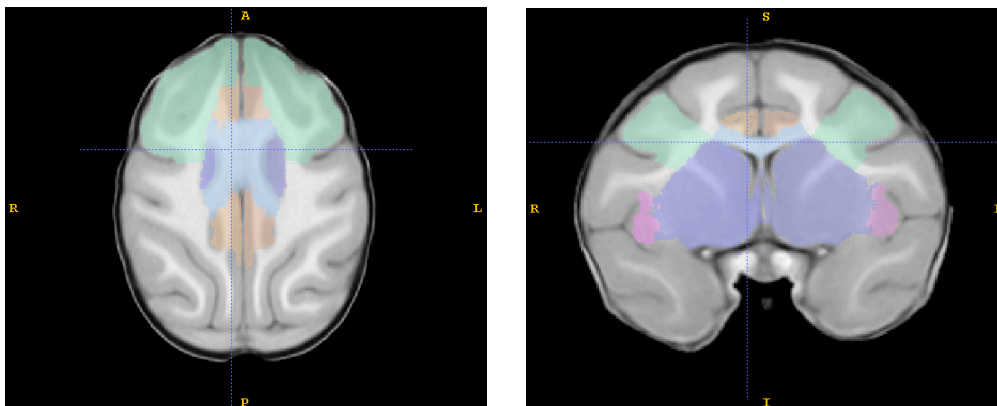


Figure VII: Prefrontal

Completed prefrontal trace (pale green) in axial (left) and coronal (right) views.

VIII. Frontal Lobe:

Major boundaries:

The frontal lobe is bounded at its superior and lateral extents by CSF at the surface of the brain. The anterior boundary is the prefrontal trace. The medial boundary is the interhemispheric fissure, and existing traces of interior structures. The posterior boundary is the central sulcus. The inferior boundary is the Sylvian Fissure in anterior portions and in the more posterior slices, a line drawn (in the coronal plane) across the central white matter between the central sulcus and the inferior extent of the corpus callosum. See figure VIII: Frontal Lobe

Tracing:

A) Mark the central sulcus in the axial and sagittal views.

- 1) Use the sagittal view, working medial to lateral, to mark the medial portion of the central sulcus. The terminal extent of the central sulcus is immediately anterior to the marginal sulcus (superior branch of the cingulate sulcus).
- 2) Use the axial view, working superior to inferior, to mark the lateral portion of the central sulcus throughout the frontal lobe.
 - b. Mark the central sulcus by labeling a narrow portion of the primary motor cortex on every third axial slice.

B) Switch to the coronal view to do the majority of the tracing. Work from anterior to posterior.

- 1) In the most anterior slices, all non-labeled brain tissue is frontal lobe. The prefrontal lobe is the anterior boundary. The interhemispheric fissure is the medial border. CSF at the extent of the brain forms all other boundaries.
- 2) When the temporal poles appear, the Sylvian fissure is the boundary between the frontal and temporal lobes.
- 3) When the central sulcus appears (as previously marked), a straight line across WM from the depth of the central sulcus to the inferior corner of the CC label defines the boundary between frontal and parietal lobes within the brain.

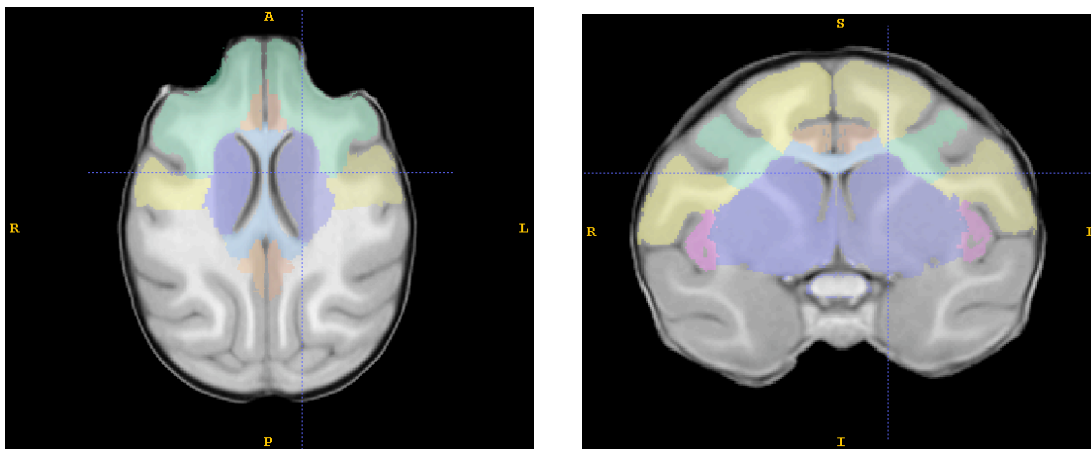


Figure VIII: Frontal Lobe

Completed frontal lobe trace (yellow) in axial (left) and coronal (right) views.

IX: Occipital Lobe:

Major boundaries:

The occipital lobe is bounded at its posterior and posterior-lateral extents by CSF at the surface of the brain. The interhemispheric fissure forms the medial boundary. The cerebellum forms the inferior boundary. The medial-anterior boundary is formed by the parietal-occipital sulcus. The lateral-anterior boundary is formed by the lunate sulcus. See figure IX: Occipital Lobe.

Tracing:

- A) Begin tracing the occipital lobe in the sagittal plane, working from medial to lateral.
- 1) The cerebellum is the inferior boundary
 - 2) CSF is the posterior boundary
 - 3) Label all unlabeled tissue, posterior to the parietal-occipital sulcus as occipital lobe.
 - 4) If the parietal-occipital sulcus no longer reaches the superior extent of the brain, cut across the narrowest portion of WM.
 - 5) When the parietal-occipital sulcus is longer clear, switch to the most lateral sagittal slice, working from lateral to medial, label all unlabeled tissue, posterior to the lunate sulcus as occipital.
 - 6) Use the axial view to check for occipital wrap, being careful to trace the right and left occipital lobes accurately.

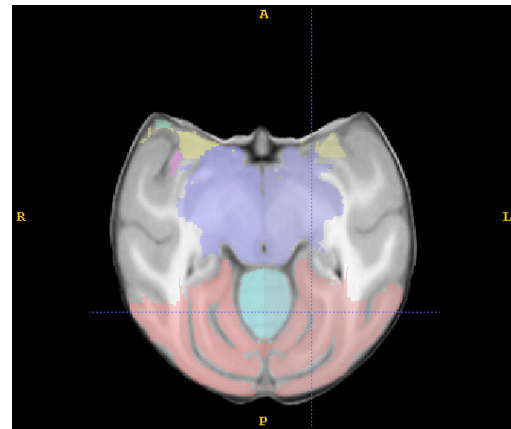
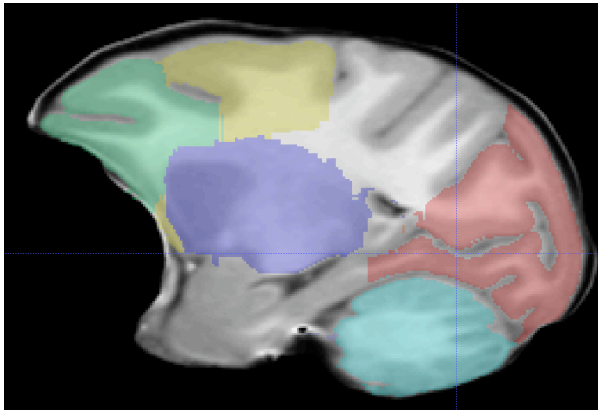


Figure IX: Occipital Lobe

Completed occipital lobe trace (red) in sagittal (left) and axial (right) views

X: Temporal Lobe: Limbic

Major boundaries:

The medial temporal lobe (or temporal lobe: limbic) is bounded at the anterior by the subcortical trace (in superior slices) and by CSF (in inferior slices). The posterior boundary is the occipital lobe. The medial boundary is formed by CSF, and the existing internal traces. The lateral boundary is the rhinal fissure and the lateral ventricle (temporal inferior horn). The superior boundary is the subcortical trace. The inferior boundary is CSF or the cerebellum. The medial temporal lobe consists primarily of the hippocampus, amygdala, and entorhinal cortex. See Figure X: Temporal Lobe: Limbic.

Tracing:

- A) Begin tracing in the axial view, working inferior to superior
- 1) The lateral boundary is the rhinal fissure and the lateral ventricle (temporal inferior horn); the medial temporal lobe should extend to, but not include, the most medial white matter branch of the temporal lobe.

- 2) The posterior boundary is the occipital lobe
- 3) The anterior boundary is CSF on the most inferior slices and the subcortical trace on more superior slices.
- 4) The medial boundary is CSF at the interior of the brain on the most inferior slices and the subcortical trace on more superior slices.
- 5) Stop tracing when you reach the axial slice where the temporal (inferior) horn of the lateral ventricle becomes the lateral ventricle trigone (atrium)

B) Review the most posterior portions of the medial temporal lobe in the coronal plane.

- 1) The hippocampus is the most posterior part of the medial temporal lobe. It includes all unlabelled tissue inferior-medial to the trigone (atrium) and inferior horn of the lateral ventricle.

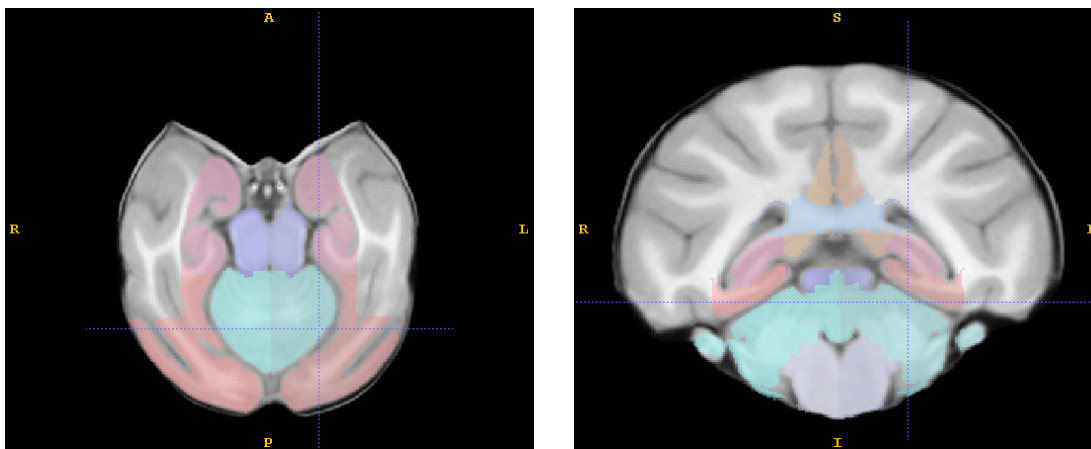


Figure XI: Temporal Lobe: Limbic

Completed trace of the limbic portion of the temporal lobe (dark pink) in axial (left) and coronal (right) views.

XI: Temporal Lobe: Auditory

Major boundaries:

The auditory temporal lobe is bounded at its anterior and lateral extents by CSF at the surface of the brain. The Sylvian Fissure is the superior boundary. The superior temporal sulcus is the inferior boundary. The medial boundary is formed by CSF, and the existing internal traces. See Figure XI: Temporal Lobe: Auditory.

A) Begin tracing in the coronal plane, work from anterior to posterior

- 1) Locate the first slice on which the superior temporal sulcus is visible
- 2) The inferior boundary of the auditory temporal lobe is the superior temporal sulcus; draw a straight line across the WM from the depth of the superior temporal sulcus to the lateral tip of the lateral ventricle to continue the inferior boundary.
- 3) The superior boundary is CSF and the frontal trace in the temporal poles, once the temporal lobes attach to the rest of the brain the Sylvian fissure and existing traces form the superior boundary.

a. When the Sylvian fissure no longer extends from the brain surface to the existing internal labels draw a straight line across the WM from the depth of the sylvian fissure to the lateral tip of the lateral ventricle to continue the superior boundary

4) The medial boundary is formed by existing traces

5) the lateral boundary is CSF at the surface of the brain

6) The posterior extent of the auditory temporal lobe is the point at which the superior temporal sulcus and sylvian fissure merge.

B) To determine which portion of the temporal poles are traced as auditory, switch to the sagittal plane, work lateral to medial.

1) To determine the inferior boundary, extend a line from the most anterior extent of the superior temporal sulcus to the surface of the brain.

2) The superior boundary is CSF and the frontal trace

3) The anterior boundary is CSF

4) Do not alter any tracing performed posterior to the slice in which the superior temporal sulcus first appears.

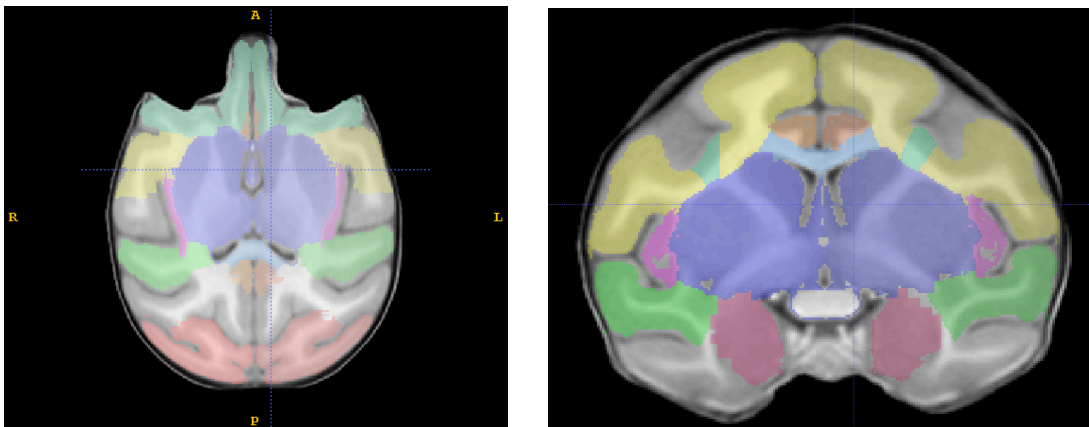


Figure XI: Temporal Lobe: Auditory

Completed trace of the auditory portion of the temporal lobe (green) in axial (right) and coronal (left) views.

XII: Temporal Lobe : Visual

Major boundaries:

The superior boundary of the visual temporal lobe is the superior temporal sulcus. The inferior boundary is CSF, the cerebellar trace, or the occipital trace. The anterior boundary is CSF. The posterior boundary is the occipital trace. The lateral boundary is CSF. The medial boundary is the medial temporal lobe trace and the lateral ventricle (and in the most posterior slices, the cingulate trace). See Figure XII: Temporal Lobe: Visual.

Tracing

A) Begin tracing in the coronal plane, working anterior to posterior

- 1) The superior boundary of the visual temporal lobe is the auditory temporal lobe trace in anterior slices. In the most posterior slices (after the sts and sylvian fissure have fused) the auditory temporal lobe trace disappears, the superior boundary is now the sts. Draw a straight line across the WM from the depth of the superior temporal sulcus to depth of the intraparietal sulcus to complete the superior boundary.
- 2) The inferior boundaries are CSF, the cerebellar trace, and the occipital trace.
- 3) The lateral boundaries are CSF
- 4) The medial boundary is the medial temporal lobe trace, the subcortical trace, and the lateral ventricle.

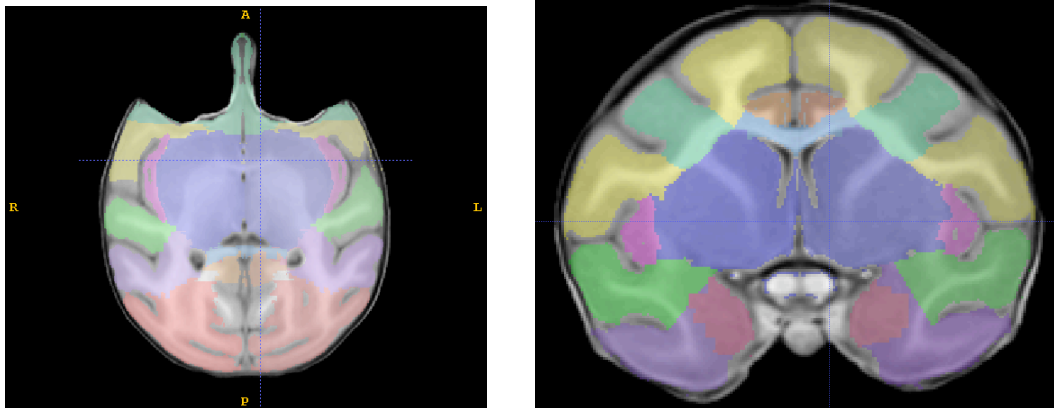


Figure XII: Temporal Lobe: Visual

Completed trace of the visual portion of the temporal lobe (purple) in the axial (left) and coronal (right) views.

XIII: Parietal Lobe:

Major boundaries:

The parietal lobe consists of all remaining cortex and central white matter not already included with other lobes. The superior and lateral boundaries are CSF at the surface the brain. The medial boundary is the interhemispheric fissure. The anterior boundary is the central sulcus. The posterior boundary is the visual temporal, auditory temporal and occipital lobes. The inferior boundary is determined by the existing traces of interior structures. See figure XIII: Parietal lobe.

Tracing:

- A) Use the coronal plane to trace the majority of the parietal lobe. Work from anterior to posterior and label all remaining cortex as parietal lobe.
- B) Check your work in all three planes.

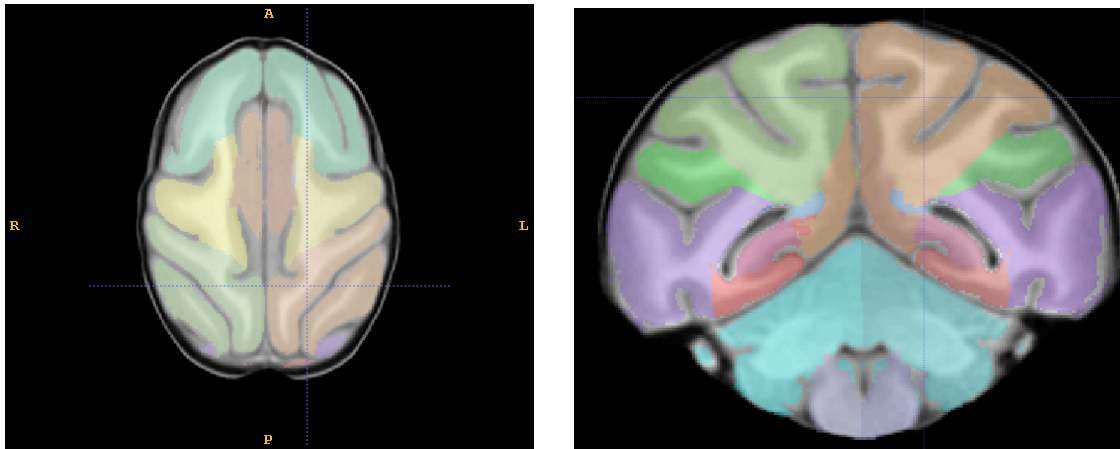


Figure XIII: Parietal Lobe

Completed trace of the parietal lobe (army green in the right hemisphere, light brown in the left hemisphere) in the axial (left) and coronal (right) views.

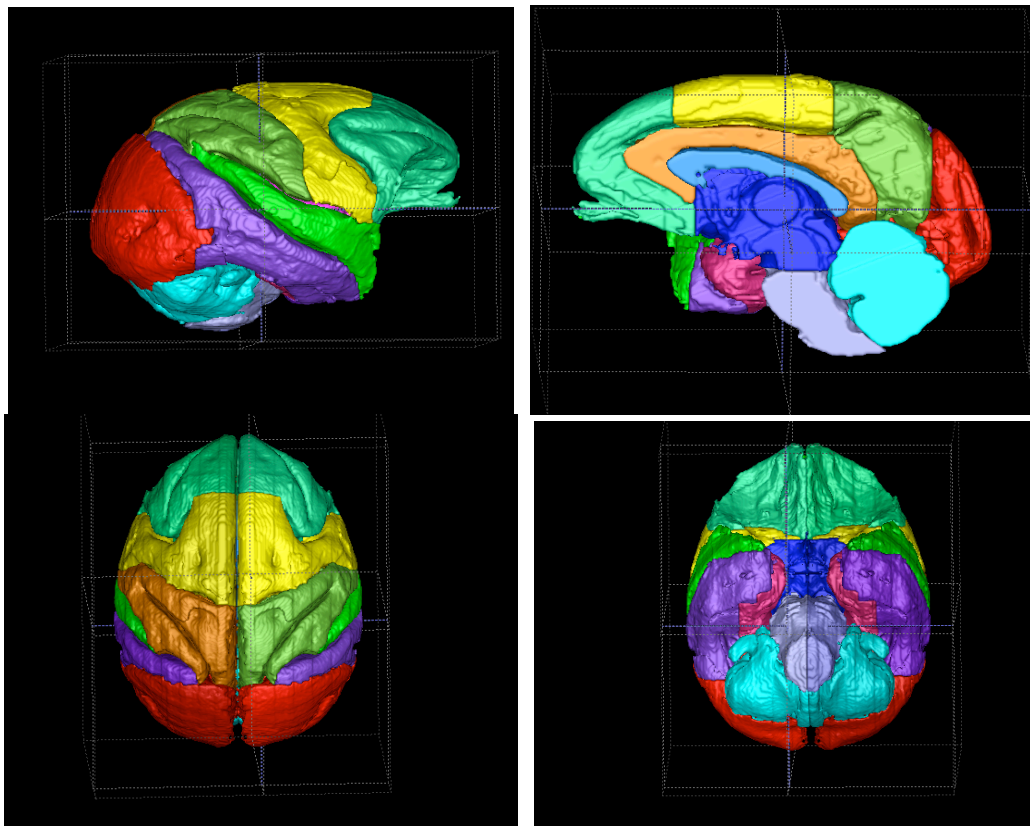


Figure XIV: 3D-mesh of parcellation clockwise from upper left: lateral, medial, superior, inferior