

Rhesus Monkey Brain Atlas: Subcortical Gray Structures

Manual Tracing for Hippocampus, Amygdala, Caudate, and Putamen

Overview of Tracing Guidelines

- A) Tracing is done in a combination of the three orthogonal planes, as specified in the detailed methods that follow.
- B) Each region of interest was originally defined in the right hemisphere. The labels were then reflected onto the left hemisphere and all borders checked and adjusted manually when necessary.
- C) For the initial parcellation, the user used the “paint over function” of IRIS/SNAP on the T1 template of the atlas.

I. Hippocampus

Major Boundaries

Superior boundary is the lateral ventricle/temporal horn in the majority of slices. At its most lateral extent (subiculum) the superior boundary is white matter. The inferior boundary is white matter. The anterior boundary is the lateral ventricle/temporal horn and the amygdala; the posterior boundary is lateral ventricle or white matter. The medial boundary is CSF at the center of the brain in all but the most posterior slices (where the medial boundary is white matter). The lateral boundary is white matter. The hippocampal trace includes dentate gyrus, the CA3 through CA1 regions of the hippocampus, subiculum, parasubiculum, and presubiculum.

Tracing

- A) Tracing is done primarily in the sagittal plane, working lateral to medial
 - a. Locate the most lateral extent of the subiculum, which is bounded on all sides by white matter, and trace.
 - b. As you page medially, tracing the hippocampus in each slice, the superior, anterior, and posterior boundaries of the hippocampus become the lateral ventricle/temporal horn.
 - c. Even further medially, the anterior boundary becomes amygdala and the posterior boundary white matter.
 - d. At the most medial slices, the hippocampal tail will no longer be present, the posterior boundary of the hippocampal head will be CSF.
- B) Review trace in the coronal and axial planes.

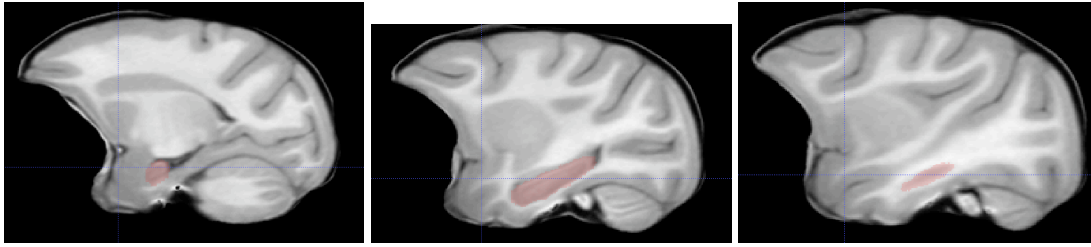

Figure 1: Hippocampal traces (in red): left-right: medial to lateral

II. Amygdala

Major Boundaries

The superior boundary is white matter (including internal capsule, optic and auditory radiations and the anterior commissure) and the putamen. The inferior boundary is the lateral ventricle/temporal horn and hippocampus in posterior coronal slices. In anterior coronal slices, the inferior boundary is temporal white matter, then CSF. The anterior boundary is CSF. The posterior boundary is hippocampus. The medial boundary is CSF. The lateral boundary is white matter in posterior coronal slices and the rhinal fissure in anterior slices. The most anterior slices include entorhinal and piriform cortex in addition to amygdala, as there is no contrast between these tissues in the most anterior slices.

Tracing

- A) Tracing is done primarily in the coronal plane.
 - a. Proceeding posterior to anterior, the amygdala is initially defined as gray matter superior to the hippocampus and separated from it by the lateral ventricle/temporal horn. It is inferior to the internal capsule, optic and auditory radiations, and the putamen. The medial boundary is CSF; the lateral boundary white matter
 - b. As you move anterior, the hippocampus and lateral ventricles diminish to be replaced entirely by the amygdala. The superior boundary is the anterior commissure, the inferior and the medial boundaries are CSF, the lateral boundary is white matter and the rhinal fissure.
 - c. Anterior to the anterior commissure, the amygdala diminishes to be replaced by CSF. CSF marks the superior, inferior, and medial boundaries. The rhinal fissure marks the lateral boundary.
- B) Review trace in the sagittal and axial planes.

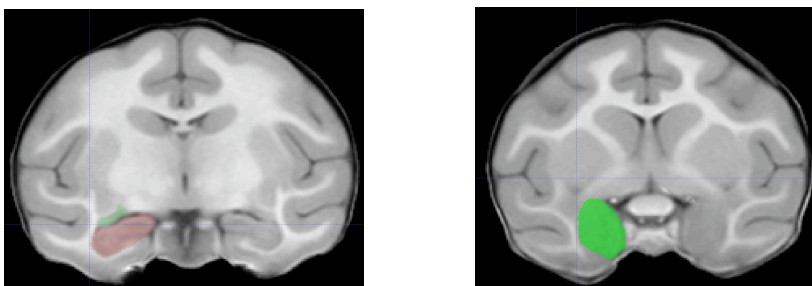


Figure 2: Amygdala traces (in green). Left picture, more posterior slice where hippocampus is still present. Right picture, more anterior slice.

III. Caudate

Major Boundaries

The most difficult boundary to assess in the caudate is the inferior boundary with the nucleus accumbens, as there is no tissue contrast border between the two structures. The most inferior slice was chosen to be the axial slice immediately superior to where the anterior commissure crosses the midline. The superior boundary is the corpus callosum. The medial boundary is the lateral ventricle. The lateral boundary is the anterior limb of the internal capsule. The anterior and posterior boundaries are white matter. The caudate tail was not included.

Tracing

- A) Tracing begins in the coronal plane.
 - a. Working from anterior to posterior outline the caudate on every 5th slice, using the boundaries defined above.
- B) Switch to the axial plane
 - a. Working superior to inferior, outline the caudate using the marks from the coronal traces as a guideline (primarily for defining the ventral-dorsal extent of the structure)
 - b. The most inferior slice in which the caudate should be outlined is the axial slice immediately superior to where the anterior commissure crosses the midline.
- C) Review trace in the sagittal plane.

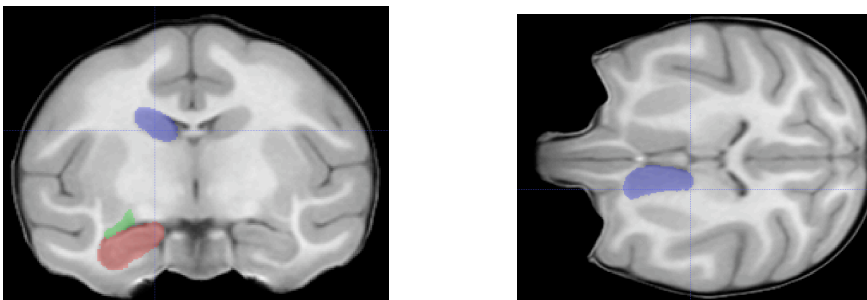


Figure 3: Caudate trace (in blue) in sample coronal (left picture) and axial (right picture) slices.

IV. Putamen

Major Boundaries

The superior, anterior, and posterior boundaries of the putamen are white matter. The medial boundary is marked by the anterior and posterior limbs of the internal capsule and the globus pallidus. The lateral boundary is the external capsule. The inferior boundary is the amygdala.

Tracing

- A) Tracing begins in the coronal plane.
 - a. Working from anterior to posterior outline the putamen on every 5th slice. Use the superior, lateral, and medial boundaries described above. However, do not extent the trace inferior to the inferior extent of the anterior commissure: the inferior extent of the putamen is best marked in the axial view.
- B) Switch to the axial plane
 - a. Working superior to inferior, outline the caudate using the marks from the coronal traces as a guideline (primarily for defining the ventral-dorsal extent of the structure). In the most inferior slices, the putamen diminishes to be replaced by the amygdala.
- C) Review trace in the sagittal plane.

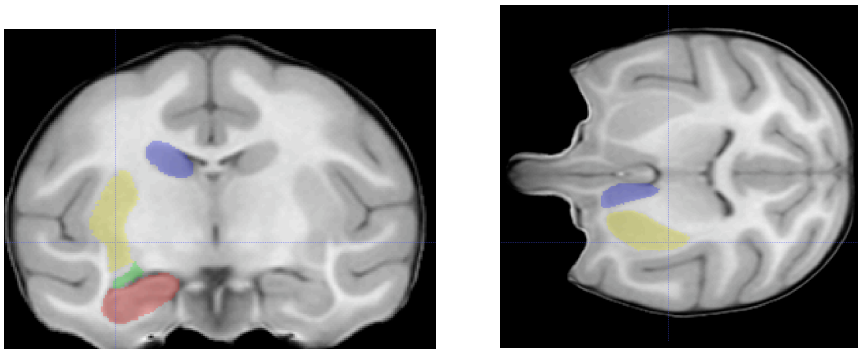


Figure 4: Putamen trace (in yellow). Sample coronal view (left picture) and sample axial view (right picture)

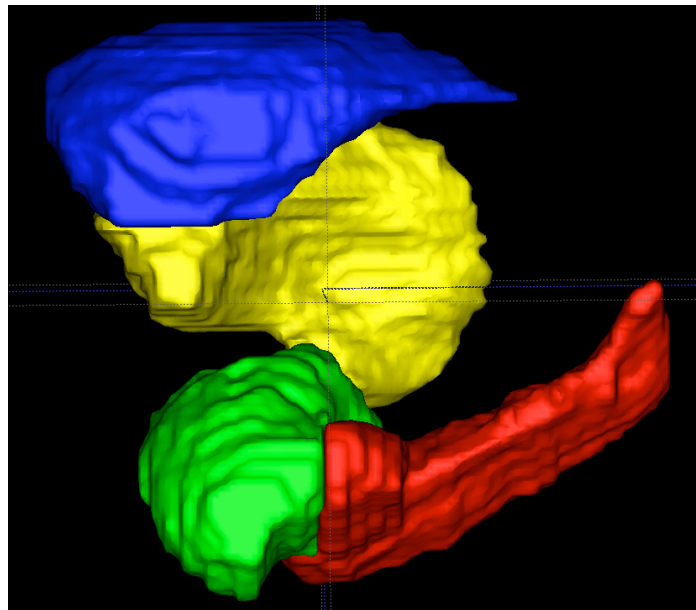


Figure 5: 3D visualization of right hemisphere segmented subcortical structures.
Hippocampus (red), Amygdala (green), Caudate (blue), Putamen (yellow)